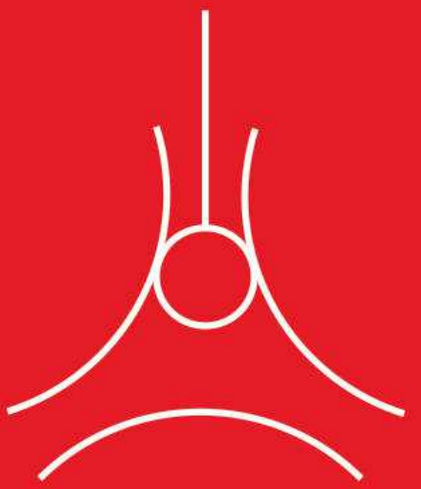

FETAL ENDOSCOPIC TRACHEAL OCCLUSION

KNOWING WHAT TO LOOK FOR MAY NOT BE EASY. KNOWING WHERE TO LOOK FOR HELP IS.

Texas Children's Fetal Center™ is home to one of the nation's largest congenital diaphragmatic hernia (CDH) programs, with outcomes among the best in the country.

Ranging from moderate to severe cases of CDH, we offer fetal endoscopic tracheal occlusion (FETO), a breakthrough research protocol with potential to dramatically improve lung growth prior to birth. Coupled with outstanding multidisciplinary, postnatal surgical care, this treatment gives more babies with CDH a chance at a healthy life. As one of the first in the country to offer FETO, with one of the most experienced staffs in North America, we're proud to be on the leading edge of this revolutionary care.

Send us your toughest cases. We're known for delivering.

Learn more: **women.texaschildrens.org/fetal** or **1-877-FetalRx**

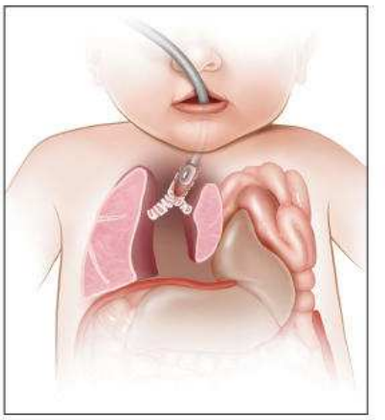

FETO is a minimally invasive procedure in which a tiny balloon is inserted into the fetus to plug the trachea. The balloon is inflated, left in place for several weeks to allow the fetus' lungs to grow, then removed a few weeks prior to delivery.

Texas Children's Hospital®

Pavilion for Women

Intrarenal Reflux

Diagnosis at Contrast-Enhanced Voiding Urosonography

Gabrielle C. Colleran, MB, BCh, BAO, Carol E. Barnewolt, MD, Jeanne S. Chow, MD, Harriet J. Paltiel, MD, CM

Vesicoureteral reflux (VUR) is a childhood condition that is usually diagnosed by fluoroscopic voiding cystourethrography (VCUG). Intrarenal reflux (IRR) of infected urine is believed to play an important role in the pathogenesis of reflux-associated pyelonephritis and subsequent parenchymal scarring and is traditionally depicted by fluoroscopic VCUG. This case series describes the phenomenon of IRR occurring in association with VUR in 4 children as depicted by contrast-enhanced voiding urosonography. The ability of contrast-enhanced voiding urosonography to show IRR when it occurs in conjunction with VUR compares favorably to that of fluoroscopic VCUG.

Key Words—contrast-enhanced voiding urosonography; intrarenal reflux; kidney; pediatric ultrasound; sonography; urinary bladder; vesicoureteral reflux; voiding cystourethrography

Vesicoureteral reflux (VUR) is one of the most common pediatric urologic abnormalities. Its prevalence is usually estimated to be approximately 1%,[1] although some authors propose that its prevalence may be substantially higher.[2,3] Fluoroscopic voiding cystourethrography (VCUG) is the generally accepted reference-standard technique for the diagnosis of VUR.[4]

Intrarenal reflux (IRR) is a rare but important phenomenon observed mainly in neonates and infants, frequently in the setting of high-grade VUR.[5] Intrarenal reflux of infected urine is believed to play an important role in the pathogenesis of reflux-associated pyelonephritis and subsequent parenchymal scarring. It has a reported incidence on fluoroscopic VCUG ranging from less than 1% to 10%.[6,7]

Contrast-enhanced voiding urosonography is an ionizing radiation–free alternative to the fluoroscopic VCUG that is used in a number of centers throughout the world in the investigation and management of VUR.[8] A limited ability to visualize IRR has been previously cited as a potential drawback of contrast-enhanced voiding urosonography when compared to VCUG.[9] In 2003, Darge et al[9] reported a single patient with IRR using Levovist (Schering AG, Berlin, Germany), a first-generation sonographic contrast agent that is no longer available on the market. We obtained Institutional Review Board (IRB) approval to perform this retrospective case review, wherein we describe the phenomenon of IRR in 4 children with VUR, as depicted by contrast-enhanced voiding urosonography using the second-generation sonographic contrast agent Optison (GE Healthcare, Princeton, NJ).

Received September 17, 2015, from the Department of Radiology, Boston Children's Hospital, and Harvard Medical School, Boston, Massachusetts USA. Revision requested October 19, 2015. Revised manuscript accepted for publication November 9, 2015.

Address correspondence to Harriet J. Paltiel, MD, CM, Department of Radiology, Boston Children's Hospital, 300 Longwood Ave, Boston, MA 02115 USA.

Abbreviations

DMSA, dimercaptosuccinic acid; IRR, intrarenal reflux; VCUG, voiding cystourethrography; VUR, vesicoureteral reflux

doi:10.7863/ultra.15.09056

Sonographic Technique

All sonographic studies were performed on a LOGIQ E9 machine (GE Healthcare, Milwaukee, WI). Grayscale images of the kidneys and bladder were obtained with C2-9, 9L, and ML6-15 probes. Contrast-enhanced imaging was performed with the C2-9 probe and the following sonographic parameters: contrast mode; amplitude modulation; mechanical index range of 0.13 to 0.16; frame rate of 10 frames per second; and focal point located immediately posterior to the kidneys, ureters, and bladder. The overall tissue gain setting was adjusted during bladder filling but not altered during subsequent imaging of the kidneys, ureters, or urethra.

Contrast-enhanced voiding urosonography was performed after the instillation of a 0.15-mL (cases 1 and 3) or a 0.3-mL (cases 2 and 4) dose of the Optison into a 250-mL bag of saline, which was then infused into the bladder by gravity. Sequential imaging of the bladder and kidneys was performed during bladder filling and voiding. Transperineal images of the urethra were obtained during voiding.

Case Descriptions

Case 1

A previously well 5-month-old girl presented with a urinary tract infection. Conventional grayscale sonography showed right mild-to-moderate hydronephrosis with moderate hydroureter (Figure 1, A and B) and left mild hydronephrosis and hydroureter (Figure 1, C and D).

There was right-sided VUR at contrast-enhanced voiding urosonography, with marked dilation of the pelvicalyceal system and ureter. Multiple punctate and linear echogenic foci were noted extending from the outer margins of the calyces and into the renal parenchyma, in keeping with IRR (Figure 1E). At the peak of reflux, there was diffuse cortical enhancement due to the presence of innumerable intraparenchymal echogenic foci (Figure 1F and Video 1). Left-sided VUR, with mild dilation of the pelvicalyceal system and ureter, was also shown (Figure 1G). Right-sided international grade V VUR[10] with IRR and left-sided grade III VUR were subsequently documented at VCUG (Figure 1H). A technetium Tc 99m dimercaptosuccinic acid (DMSA) study performed 7 weeks later showed differential renal function of 48% on the right and 52% on the left. Slight cortical thinning of the lower right renal pole was identified (Figure 1I). There were no other sites of cortical scarring or focal parenchymal defects.

Figure 1. Case 1. **A**, Sagittal sonogram shows mild-to-moderate dilation of the right renal calyces and pelvis (arrows). **B**, Sagittal sonogram depicts moderate dilation of the distal right ureter (arrow). There is a small amount of free fluid in the pelvis (asterisk). B indicates bladder. **C**, Sagittal sonogram shows mild dilation of the left renal calyces and pelvis (arrows). (continued)

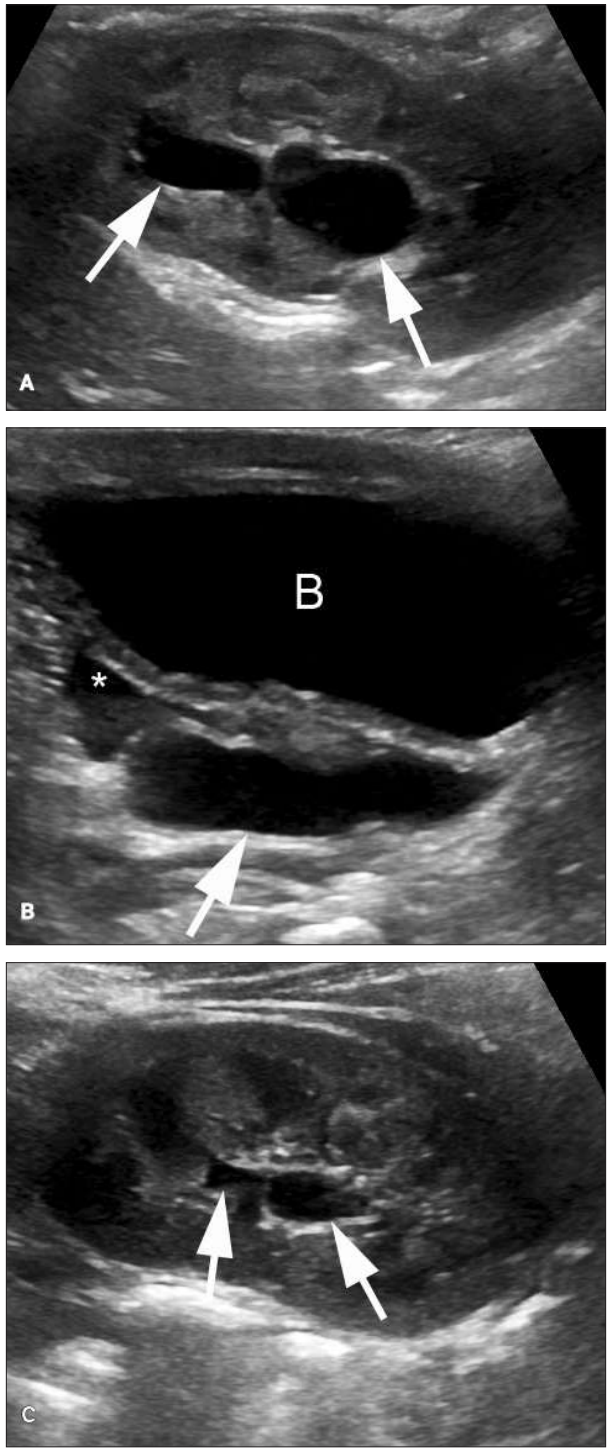

Figure 1. (continued) **D**, Sagittal sonogram shows mild dilation of the distal left ureter (arrow). **E**, Sagittal sonogram of the right flank during contrast-enhanced voiding urosonography shows contrast material filling a dilated, tortuous ureter (arrow) and a dilated renal collecting system with blunted calyces (asterisks). Multiple punctate and linear hyperechoic foci, in keeping with IRR, extend from the calyces into the adjacent renal parenchyma (arrowheads), most prominently from the lowermost calyx. **F**, Sagittal sonogram of the right kidney during contrast-enhanced voiding urosonography depicts widespread renal parenchymal enhancement at the peak of reflux due to IRR (arrowheads). Asterisks indicate dilated calyces. **G**, Sagittal sonogram of the left flank during contrast-enhanced voiding urosonography reveals contrast material within a mildly dilated ureter (arrow) and renal collecting system (asterisks). There is no IRR, and the surrounding renal parenchyma appears dark. **H**, Anteroposterior supine image of the abdomen and pelvis during VCUG shows grade V right-sided VUR with a dilated ureter (U), pelvis (asterisk), and calyces. There is extensive right IRR (arrowheads). Left-sided grade II to III VUR is also present (arrow). **I**, Posterior oblique pinhole image of the right kidney on Tc-99m-DMSA scintigraphy shows mild lower pole parenchymal thinning (arrow).

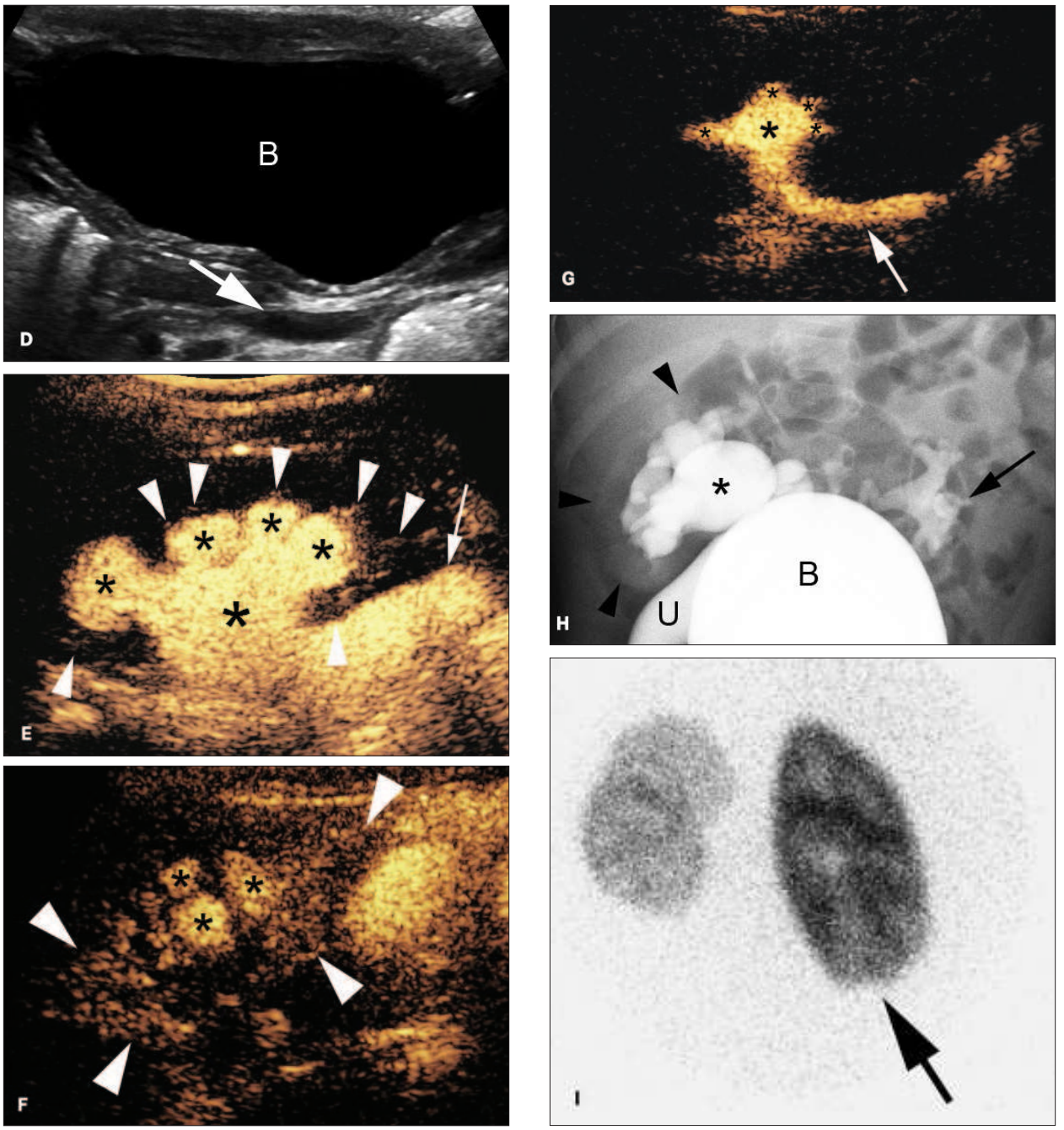

Case 2

A previously healthy girl developed a urinary tract infection at 8 months of age. Left-sided hydronephrosis had been diagnosed both prenatally and postnatally, but the child did not receive prophylactic antibiotic therapy. Subsequent sonography at the time of clinical presentation revealed minimal residual left hydronephrosis (Figure 2A) without hydroureter and a normal right kidney without hydroureter.

At contrast-enhanced voiding urosonography, severe left-sided VUR was shown, with a dilated, tortuous ureter; a dilated renal pelvis with dilated, blunted calyces; and IRR (Figure 2, B and C, and Video 2). No right-sided reflux was documented. Grade IV to V left VUR with IRR was confirmed on the VCUG performed immediately afterward (Figure 2D). A Tc 99m DMSA study done 1 week later revealed multiple left-sided cortical defects throughout the kidney and a moderate-sized right upper pole cortical defect (Figure 2, E and F).

Case 3

An 8-day-old boy was sent for VCUG because of a prenatal diagnosis of hydronephrosis. Mild-to-moderate left hydronephrosis with moderate-to-severe hydroureter was documented on renal sonography (Figure 3, A and B). The right kidney appeared normal (Figure 3C).

Contrast-enhanced voiding urosonography revealed high-grade bilateral VUR, which was more pronounced on the left (Figure 3D), and IRR on the right (Figure 3, E and F, and Video 3). Voiding cystourethrography showed bilateral grade IV to V VUR with right-sided IRR (Figure 3G). A Tc 99m DMSA study was not obtained.

Case 4

A 1-month-old boy was referred for VCUG because of a history of high-grade VUR in a male sibling. Mild-to-moderate left-sided hydronephrosis without hydroureter was seen on renal sonography (Figure 4A). The right kidney appeared normal (Figure 4B)

High-grade left-sided VUR with moderate-to-severe dilation of the ureter and renal collecting system was shown at contrast-enhanced voiding urosonography, as well as mild IRR into the mid and lower pole renal parenchyma (Figure 4C and Video 4). Reflux into a minimally dilated right ureter and collecting system was also noted (Figure 4D). Voiding cystourethrography performed immediately afterward revealed only grade I right-sided VUR without evidence of left-sided VUR (Figure 4, E and F). A Tc 99m DMSA study was not obtained.

Figure 2. Case 2. **A**, Sagittal sonogram shows mild dilation of the left renal calyces and pelvis (arrows). **B**, Sagittal sonogram of the left flank during contrast-enhanced voiding urosonography depicts contrast material within a markedly dilated ureter (arrows) and a dilated renal pelvis and collecting system with blunted calyces (asterisks). Multiple punctate hyperechoic foci are present within the mid- and lower renal pole parenchyma, in keeping with IRR (arrowheads). (continued)

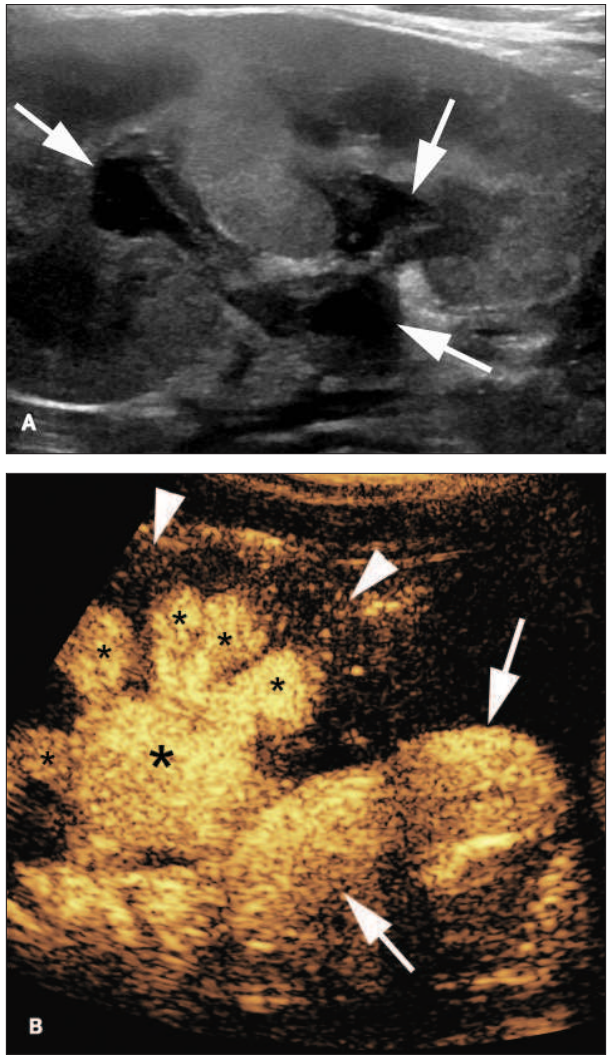

Figure 2. (continued) **C**, Sagittal sonogram of the left kidney during contrast-enhanced voiding urosonography reveals diffuse parenchymal enhancement at the peak of reflux due to the presence of IRR. **D**, Anteroposterior supine image of the abdomen and pelvis during VCUG shows grade IV to V left-sided VUR with a dilated ureter, pelvis, and calyces. There is striking left IRR (arrowheads). **E**, Posterior pinhole image of the left kidney on Tc-99m-DMSA scintigraphy reveals multiple cortical defects (arrowheads). **F**, Posterior pinhole image of the right kidney on Tc-99m-DMSA scintigraphy shows a prominent upper pole defect (arrowhead).

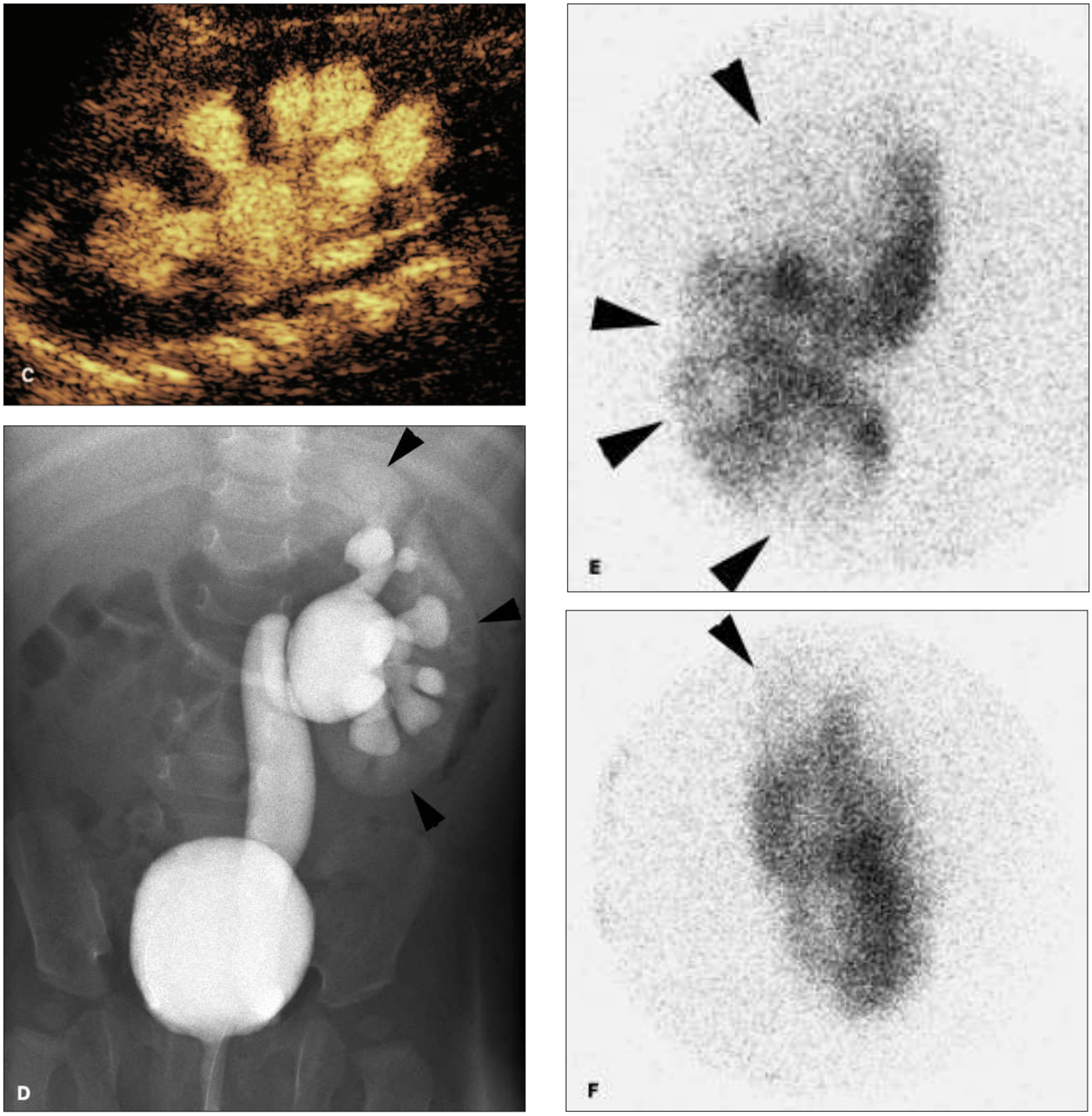

Figure 3. Case 3. **A**, Sagittal sonogram reveals mild-to-moderate dilation of the left renal collecting system (arrows). **B**, Sagittal sonogram depicts moderate-to-severe dilation of the distal left ureter (arrow) posterior to the bladder (B). **C**, Normal sagittal sonogram of the right kidney. There is no ureteral dilation. **D**, Sagittal sonogram of the left flank during contrast-enhanced voiding urosonography shows contrast material filling a dilated ureter (arrow), a dilated renal pelvis, and dilated, blunted calyces (asterisks). There is no IRR, and the surrounding renal parenchyma is dark. (continued)

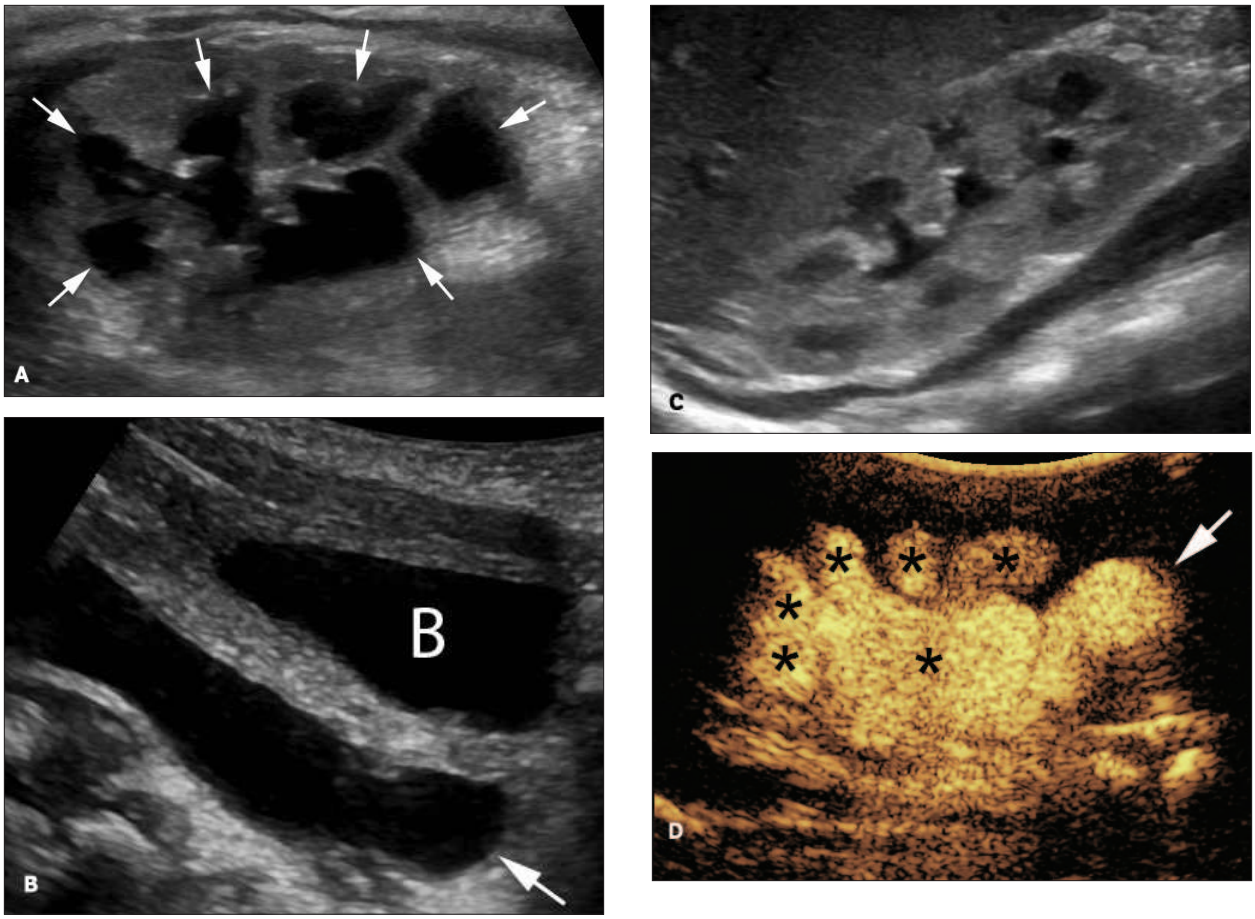

Discussion

Vesicoureteral reflux is identified in 30% to 50% of all children, boys and girls, presenting with a first urinary tract infection[11] and in 27.4% of siblings of patients with documented VUR.[12] Although traditionally VUR is investigated with fluoroscopic VCUG, limited sensitivity due to intermittent fluoroscopy and concerns about childhood radiation exposure have led to the search for an effective, radiation-free alternative to VCUG.[13]

The development of sonographic contrast agents along with advances in sonographic harmonic imaging software that substantially enhance signal-to-noise ratios have resulted in the development of contrast-enhanced voiding urosonography as an effective imaging technique for the investigation and management of VUR.[8,13] Many recent studies have shown increased sensitivity of contrast-enhanced voiding urosonography for the diagnosis of VUR compared to fluoroscopic VCUG. Wong et al[13] demonstrated sensitivity and specificity of 100% and 85%, respectively, of contrast-enhanced voiding urosonography for reflux detection compared to fluoroscopic VCUG. Their results are concordant with a large review by Darge,[14] which concluded that contrast-enhanced voiding urosonography is more sensitive than fluoroscopic VCUG for the detection of VUR.

Cases of VUR accompanied by IRR are generally considered to be at the more severe end of the clinical spectrum.[5] Intrarenal reflux occurs in association with compound renal papillae found in the polar regions of the kidney and acts as a marker for potential sites of renal parenchymal scarring.[15] Animal models of VUR in piglets have shown that a com-

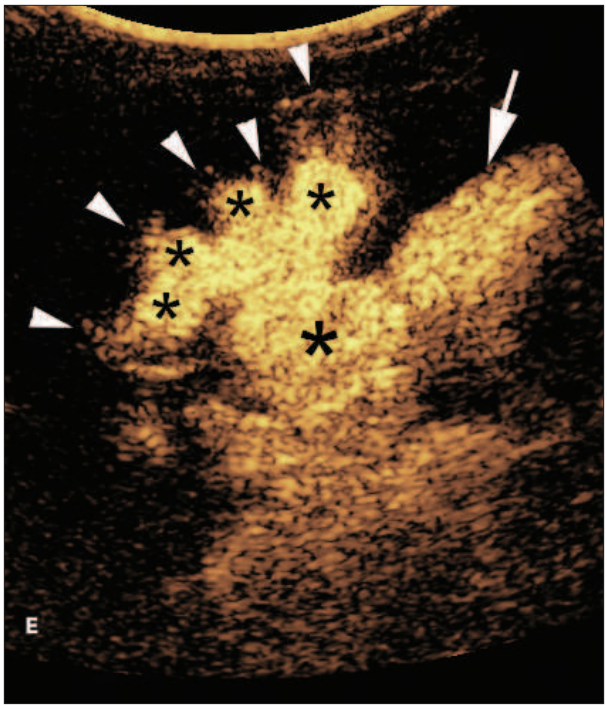

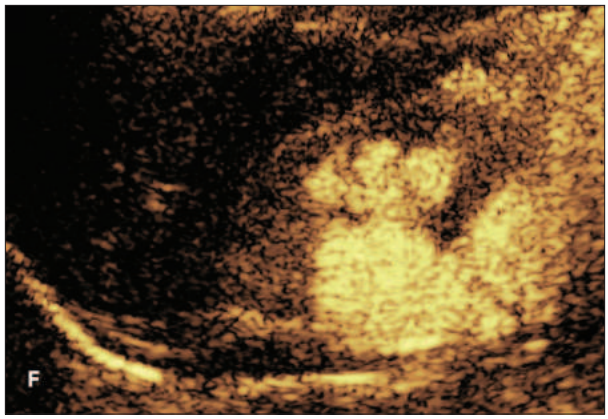

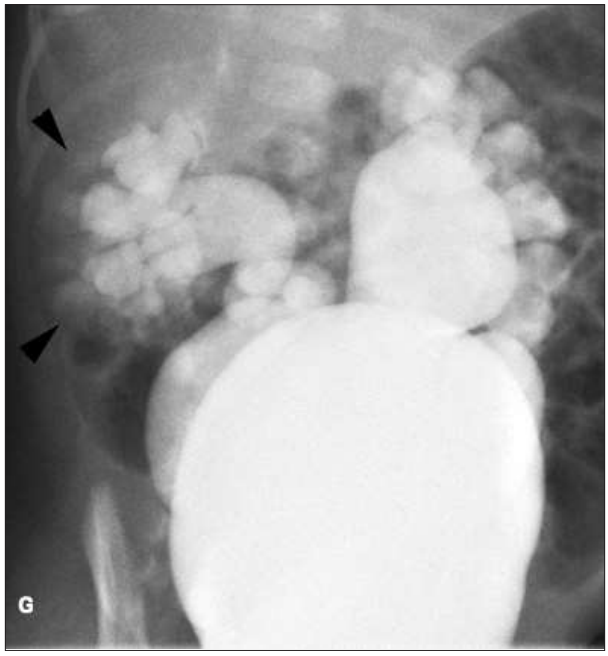

Figure 3. (continued) **E**, Sagittal sonogram of the right flank during contrast-enhanced voiding urosonography reveals contrast material in a dilated ureter (arrow), a dilated renal pelvis, and dilated, blunted calyces (asterisks). Intrarenal reflux is seen as halolike hyperechoic foci in the lower pole renal parenchyma with less prominent punctate hyperechoic foci in the mid and upper renal parenchyma (arrowheads). **F**, Sagittal sonogram of the right flank during contrast-enhanced voiding urosonography at the height of reflux shows diffuse renal parenchymal enhancement. **G**, Anteroposterior supine image of the abdomen and pelvis during VCUG shows bilateral grade IV to V VUR with dilated ureters, pelves, and calyces. There is substantial right IRR (arrowheads).

bination of VUR, IRR, and infection is required for scarring to evolve.[16] The presence of renal scarring is of prognostic importance, as it is associated with the long-term development of hypertension and chronic renal failure.[17,18]

Although clinical management decisions are based primarily on reflux grade and not on the presence or absence of IRR, its presence aids risk stratification and may influence management.[9] A recent prospective case-control study found that baseline Tc 99m DMSA findings were worse in an IRR group than a non-IRR group, although similar rates of reflux resolution and urinary tract infections were observed in both groups with medical treatment.[19] Similarly, a retrospective study of 50 patients with IRR and VUR demonstrated that cortical defects on Tc 99m DMSA correlated well with sites of IRR.[5] Some authors advocate that interventions such as ureteral reimplantation should be considered sooner in children with IRR than in those without IRR.[20]

In this case series, IRR was manifested as linear, punctate, and halolike echogenic foci extending into the renal parenchyma from the base of the calyces. At the peak of reflux, extensive IRR resulted in diffuse renal cortical enhancement, as illustrated in cases 1, 2, and 3. Only 3 of the 4 children in our series with IRR depicted by contrast-enhanced voiding urosonography had IRR depicted by fluoroscopic VCUG. This finding suggests that the ability of

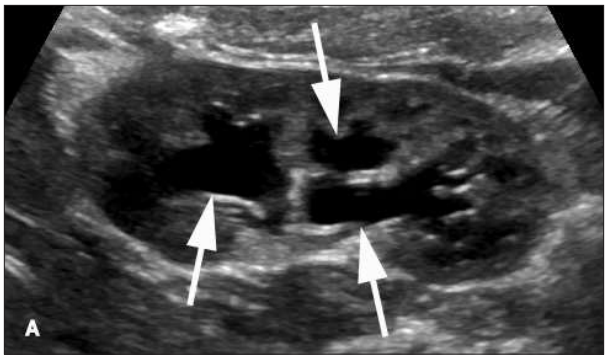

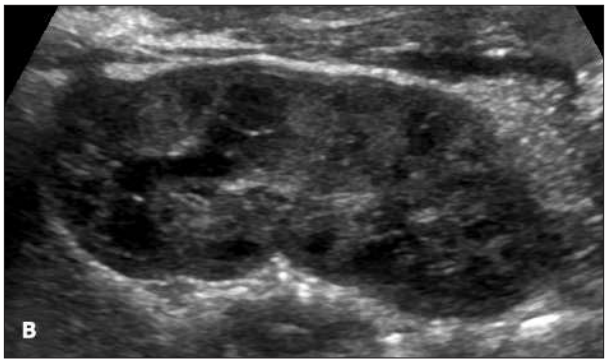

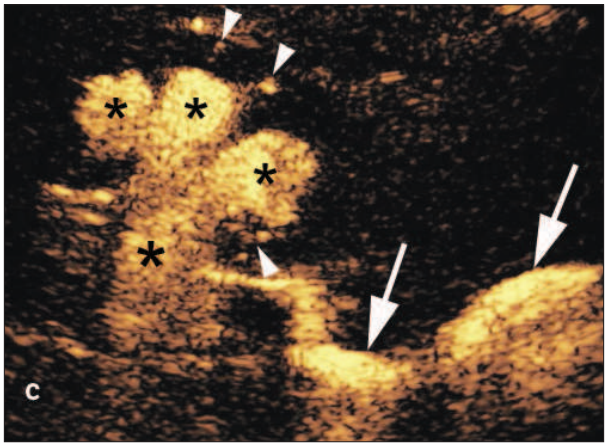

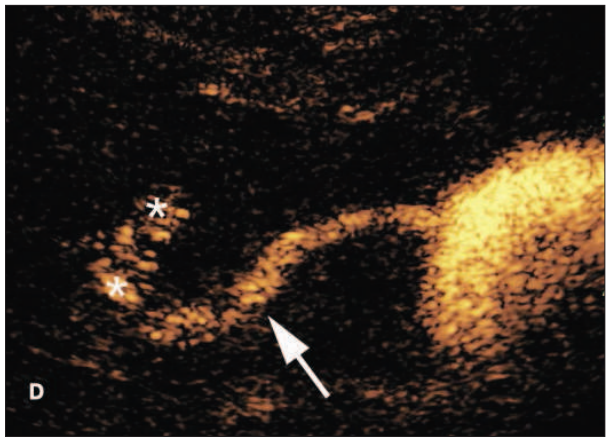

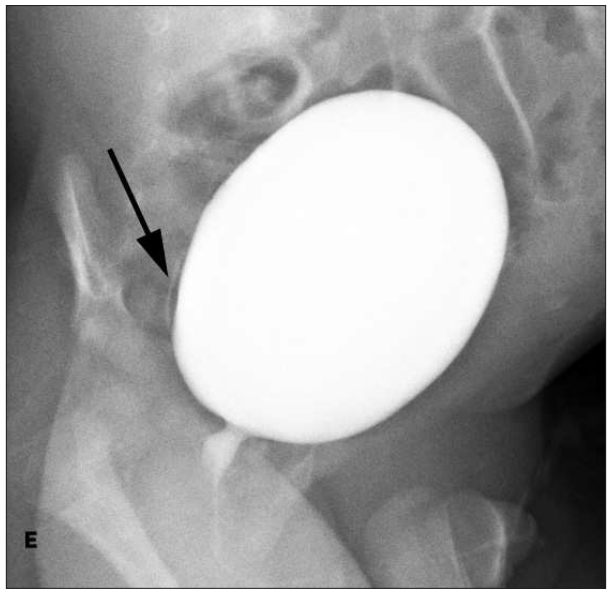

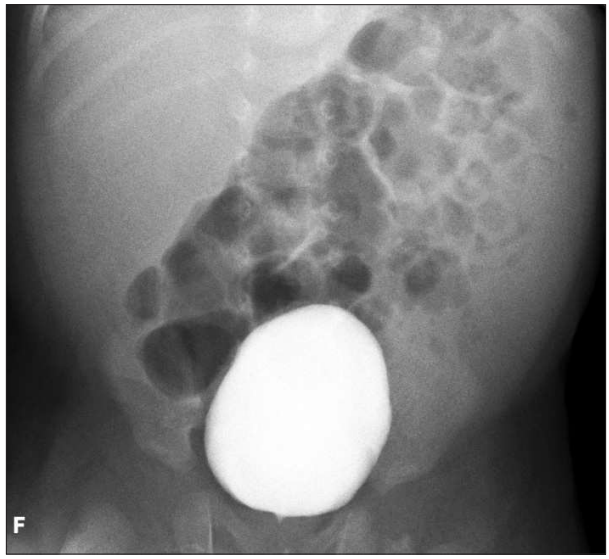

Figure 4. Case 4. **A**, Sagittal sonogram shows mild-to-moderate dilation of the left renal calyces and pelvis (arrows). **B**, Normal sagittal sonogram of the right kidney. There is no ureteral dilation. **C**, Sagittal sonogram of the left flank during contrast-enhanced voiding urosonography shows a dilated, tortuous ureter (arrows), dilated renal pelvis, and blunted calyces (asterisks). Scattered punctate hyperechoic lower pole parenchymal foci are in keeping with IRR (arrowheads). **D**, Sagittal sonogram of the right flank during contrast-enhanced voiding urosonography reveals contrast material within a minimally dilated ureter (arrow) and renal collecting system (asterisks). There is no IRR, and the surrounding renal parenchyma appears dark. **E**, Right anterior oblique image of the pelvis during VCUG depicts minimal right-sided VUR (arrow). **F**, Anteroposterior supine image of the abdomen and pelvis after voiding during VCUG reveals no residual contrast within the right ureter. No contrast material is identified within either renal fossa or in the left ureter.

contrast-enhanced voiding urosonography to show IRR when it occurs in conjunction with VUR compares favorably to that of fluoroscopic VCUG. We speculate that the volume of IRR in case 4 was relatively low in comparison to cases 1, 2, and 3, which may explain the fact that no IRR was depicted on the corresponding VCUG.

In conclusion, to our knowledge, a case series depicting IRR at contrast-enhanced voiding urosonography using a second generation sonographic contrast agent has not been reported previously. The ability of contrast-enhanced voiding urosonography to show IRR when it occurs in conjunction with VUR compares favorably to that of fluoroscopic VCUG.

References

1. Diamond DA, Mattoo TK. Endoscopic treatment of primary vesicoureteral reflux. *N Engl J Med* 2012; 366:1218–1226.
2. Sargent MA. What is the normal prevalence of vesicoureteral reflux? *Pediatr Radiol* 2000; 30:587–593.
3. Venhola M, Hannula A, Huttunen NP, Renko M, Pokka T, Uhari M. Occurrence of vesicoureteral reflux in children. *Acta Paediatr* 2010; 99:1875–1878.
4. Tullus K. Vesicoureteral reflux in children. *Lancet* 2015; 385:371–379.
5. Kim SW, Im YJ, Hong CH, Han SW. The clinical significance of intrarenal reflux in voiding cystourethrography (VCUG). *Korean J Urol* 2010; 51:60–63.
6. Gotoh T, Asano Y, Nonomura K, Togashi M, Koyanagi T. Intrarenal reflux in children with vesicoureteral reflux. *Nippon Hinyokika Gakkai Zasshi* 1991; 82:1480–1486.
7. Cremin BJ. Observations on vesico-ureteric reflux and intrarenal reflux: a review and survey of material. *Clin Radiol* 1979; 30:607–621.
8. Darge K. Voiding urosonography with US contrast agent for the diagnosis of vesicoureteral reflux in children: an update. *Pediatr Radiol* 2010; 40:956–962.
9. Darge K, Trusen A, Gordjani N, Riedmiller H. Intrarenal reflux: diagnosis with contrast-enhanced harmonic US. *Pediatr Radiol* 2003; 33:729–731.
10. Lebowitz RL, Olbing H, Parkkulainen KV, Smellie JM, Tamminen-Mobius TE. International system of radiographic grading of vesicoureteric reflux. International Reflux Study in Children. *Pediatr Radiol* 1985; 15:105–109.
11. Greenfield SP, Wan J. Vesicoureteral reflux: practical aspects of evaluation and management. *Pediatr Nephrol* 1996; 10:789–794.
12. Skoog SJ, Peters CA, Arant BS Jr, et al. Pediatric Vesicoureteral Reflux Guidelines Panel summary report: clinical practice guidelines for screening siblings of children with vesicoureteral reflux and neonates/infants with prenatal hydronephrosis. *J Urol* 2010; 184:1145–1151.
13. Wong LS, Tse KS, Fan TW, et al. Voiding urosonography with second-generation ultrasound contrast versus micturating cystourethrography in the diagnosis of vesicoureteric reflux. *Eur J Pediatr* 2014; 173:1095–1101.
14. Darge K. Voiding urosonography with US contrast agents for the diagnosis of vesicoureteric reflux in children, II: comparison with radiological examinations. *Pediatr Radiol* 2008; 38:54–63.
15. Ransley PG. Intrarenal reflux: anatomical, dynamic and radiological studies, part 1. *Urol Res* 1977; 5:61–69.
16. Arnold AJ, Sunderland D, Hart CA, Rickwood AM. Reconsideration of the roles of urinary infection and vesicoureteric reflux in the pathogenesis of renal scarring. *Br J Urol* 1993; 72:554–556.
17. Goonasekera CD, Dillon MJ. Hypertension in reflux nephropathy. *BJU Int* 1999; 83(suppl 3):1–12.
18. Gebäck C, Hansson S, Martinell J, Sandberg T, Sixt R, Jodal U. Renal function in adult women with urinary tract infection in childhood. *Pediatr Nephrol* 2015; 30:1493–1499.
19. Boubnova J, Sergent-Alaoui A, Deschenes G, Audry G. Evolution and prognosis value of intrarenal reflux. *J Pediatr Urol* 2011; 7:638–643.
20. Kanumakala S, Kalidasan V, Kenney I. Intra-renal reflux [letter]. *Arch Dis Child* 2004; 89:692.