EcoVue®
Ultrasound Gel

Change Your Vue.

Introducing the next generation of ultrasound gel...EcoVue®. Ergonomically designed for ease-of-use, the eco-friendly FlexPac® creates higher product-to-package ratio reducing waste and improving sustainability. Designed with patient safety in mind, our non-refillable & single use products will forever *Change Your Vue* of ultrasound gel.

Sustainable Packaging

Natural Ingredients

Reduces CO^2 Footprint

EcoVue.com

Exoanal Imaging of the Anal Sphincters

Hans Peter Dietz, MD, PhD, FRANZCOG, DDU, CU

Since its introduction in the early 1990s, endoanal sonography has become the mainstay of morphologic assessment of the anal canal and sphincter, especially for obstetric anal sphincter trauma. Lack of availability of suitable systems and the invasive nature of the method have limited uptake and clinical utility. More recently, exoanal or transperineal/translabial tomographic imaging has been developed as a noninvasive alternative. This pictorial overview aims to introduce the reader to this new diagnostic modality and to demonstrate common findings in asymptomatic and symptomatic women.

Key Words—anal sphincter; birth trauma; exoanal sonography; fecal incontinence; 4-dimensional sonography; gynecologic ultrasound; pelvic floor

Until very recently, imaging of the external and internal anal sphincters has almost exclusively been undertaken by endoanal sonography using high-resolution transducers with a field of vision of 360°. Since its introduction in the early 1990s, this method has become firmly established as a core component of a colorectal diagnostic workup for anal incontinence and is covered extensively in the colorectal and radiological literature.[1–4] Not surprisingly, given the prominence of obstetric anal sphincter trauma in the etiology of anatomic abnormalities of the sphincter, obstetricians have contributed to the popularization of this technology.[5]

However, because of the limited availability of ultrasound systems capable of endoanal imaging relative to other systems, practitioners have experimented with high-frequency curved array transducers placed exoanally (ie, transperineally) since the mid-1990s.[6] This approach involves placing a transducer on the perineum (Figure 1) but in the coronal rather than the midsagittal plane as is usual for pelvic floor imaging. Although there were a number of small studies using this approach for comparative assessments,[7,8] none of them were large enough to allow for a conclusive evaluation of this technique, and more widespread uptake of the technique was lacking, at least partly because of limited tissue discrimination.

Over the last few years, there have been an increasing number of publications on the use of volume sonography to image the sphincter,[9–19] which has the advantage of giving access to all 3 orthogonal planes at the same time. Since 2012, our unit has attempted to standardize and validate a tomographic method for showing the entire sphincter[20] to improve repeatability and validity of the method. Now that the imaging quality of 3-dimensional (3D)/4-dimensional (4D) systems has matured, tomographic translabial sonography has the potential to replace endoanal imaging altogether. The technique seems highly repeatable[21] and is available on all ultrasound systems allowing multislice volume imaging. Hopefully this method will allow maternal birth trauma (ie, levator and anal sphincter trauma) to

Received March 30, 2017, from the Department of Obstetrics and Gynecology, Sydney Medical School Nepean, Penrith, New South Wales, Australia. Manuscript accepted for publication April 21, 2017.

Address correspondence to Hans Peter Dietz, MD, PhD, FRANZCOG, DDU, CU, Department of Obstetrics and Gynecology, Sydney Medical School Nepean, University of Sydney, Nepean Hospital, 61 Derby St, Kingswood, NSW 2751, Australia.

E-mail: hpdietz@bigpond.com

Abbreviations
4D, 4-dimensional; 3D, 3-dimensional

doi:10.1002/jum.14246

become a key performance indicator of maternity services[22] in the near future.

Equipment and Basic Technique

Originally, translabial sphincter imaging was performed with curved array B-mode transducers,[23] as in Figure 2, which tend to be too close to the tissues of interest, and such transducers were of limited utility for the purpose. Volume transducers, however, have the advantage of an inbuilt "standoff pad." A curved array of piezoelectric crystals oscillates in an oil bath rather than being in direct contact with the patient's skin. Transverse transducer placement (as shown in Figure 1) makes it easier to keep a minimum distance from the structures in question, with lateral aspects of the transducers resting on the vulva or thigh, allowing focusing on the area of greatest interest (ie, the first 2 cm). If the perineum is short

Figure 1. Transducer placement for translabial anal sphincter imaging (**A**) and schematic representation of structures imaged (**B**). EAS indicates external anal sphincter; and IAS, internal anal sphincter. Reproduced with permission from Dietz HP. Pelvic floor ultrasound. In: Fleischer AC, Toy E, Manning F, et al (eds). *Sonography in Obstetrics and Gynecology: Principles and Practice*. 8th ed. New York, NY: McGraw Hill; 2016.

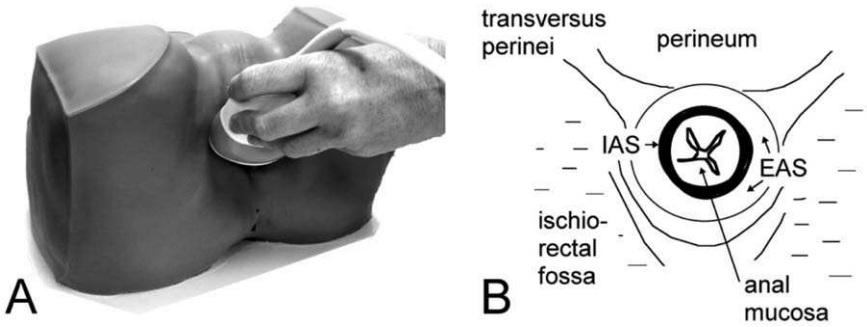

Figure 2. Transverse exoanal/perineal imaging of the anal sphincter 2 months after repair of a third-degree tear, using a curved array 2-dimensional transducer (9–4 MHz) at the maximum frequency. There is a poorly repaired third-degree tear (arrows), seen in 2 slices obtained at the mid and cranial aspects of the external sphincter.

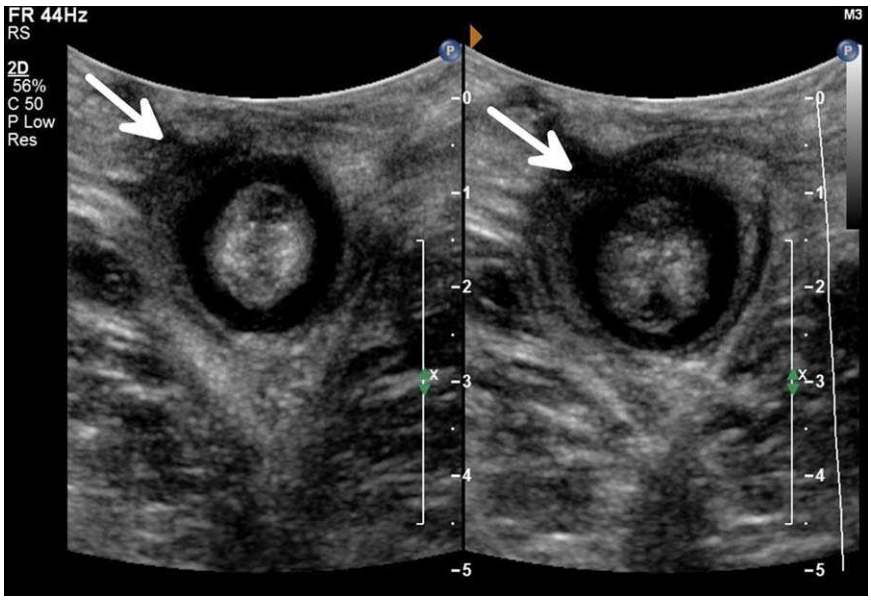

or deficient, a steeper transducer placement (ie, closer to the vertical plane) will allow vulval tissues to be used as a standoff pad.

Usually, acquisition and aperture angles are reduced relative to pelvic floor imaging for levator ani morphologic characteristics and prolapse, at 60° to 70° for both. Harmonics are set to high, and the transducer frequency maximized to optimize resolutions so that the effective frequency is 6 to 8 MHz. These settings provide volume data sets that can be sliced at arbitrary locations in all 3 orthogonal planes (Figure 3). Even more conveniently, a tomographic representation of the resulting volume can effectively image virtually the entire external anal sphincter, with the possible exception of the most distal subcutaneous aspects of the muscle, the visibility of which can be impaired by artifact (Figure 4). This set of slices at predetermined locations is based on identifying the cranial termination of the external anal sphincter and the caudal termination of the internal anal sphincter (Figure 5).

As in the case of levator assessment, exoanal sphincter imaging is undertaken on pelvic floor muscle contraction. This action seems to enhance tissue discrimination, but we have not been able to demonstrate any advantage in terms of validity.[24] A pelvic floor muscle contraction may also provide for a basic form of functional assessment, with a reduction in area showing constriction of the anal canal by the external anal sphincter. The mucosa is visualized as a hyperechoic area, often star shaped, representing the mucosal folds of the anal canal.[9] The internal anal sphincter is seen as a hypoechoic ring and the external anal sphincter as an isoechoic to hyperechoic ring surrounding the internal sphincter (Figures 3 and 4). There may be some variation of appearances depending on age, which seems to lead to thickening of the internal anal sphincter,[25] and hormonal status. In general, imaging tends to be poorer in older women because of perineal scarring, urogenital atrophy, and narrowing of the introitus. Sometimes, especially in the obese, it may be necessary to exert pressure on the perineum, which may become uncomfortable for a patient with marked atrophy.

If imaging conditions are good, such as in younger women without major degrees of perineal scarring, subdivisions of the external anal sphincter and the longitudinal muscle of the anus can be identified. The latter occasionally causes minor problems with the identification of the cranial limit of the external anal sphincter

Figure 3. Orthogonal views of external and internal anal sphincters (EAS and IAS) and anal mucosa on 3D/4D translabial sphincter imaging. The top left image is the coronal plane; top right is midsagittal; and bottom left is an axial view of the anal canal. Reproduced with permission from Dietz HP. Pelvic floor ultrasound. In: Fleischer AC, Toy E, Manning F, et al (eds). *Sonography in Obstetrics and Gynecology: Principles and Practice*. 8th ed. New York, NY: McGraw Hill; 2017. © 2017 by McGraw-Hill Education.

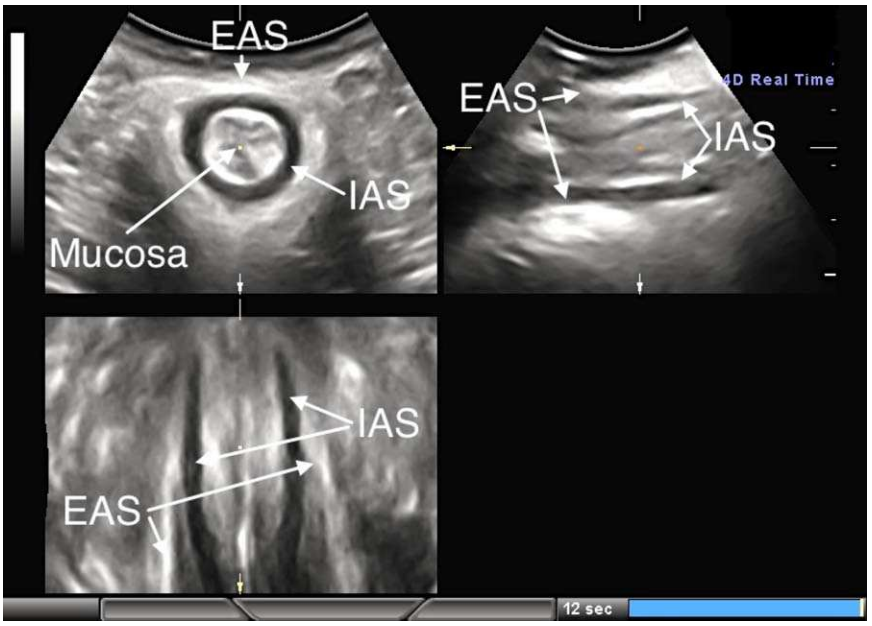

Figure 4. Tomographic translabial imaging of a normal anal sphincter in a nulliparous patient. The top left image shows the midsagittal plane; the remaining 8 images represent coronal slices through the anal canal. The locations of those slices are given by the vertical lines in the midsagittal plane. Slice 1 is represented by the leftmost vertical line in the top left image; slice 8 is the bold line at the right of the midsagittal plane image. The arrows illustrate the landmarks used to place these slices in the midsagittal plane: the left arrow indicates the cranial margin of the external sphincter; the right arrow indicates the caudad margin of the internal sphincter. Slice 1 is located above the external anal sphincter; slice 8 is located below the internal anal sphincter within the subcutaneous component of the external anal sphincter. Reproduced with permission from Shek KL, Della Zazzera V, Kamisan Atan I, Guzman Rojas R, Langer S, Dietz HP. The evolution of transperineal ultrasound findings of the external anal sphincter during the first years after childbirth. *Int Urogynecol J* 2016; 27:1899–1903. ©The International Urogynecological Association 2016.

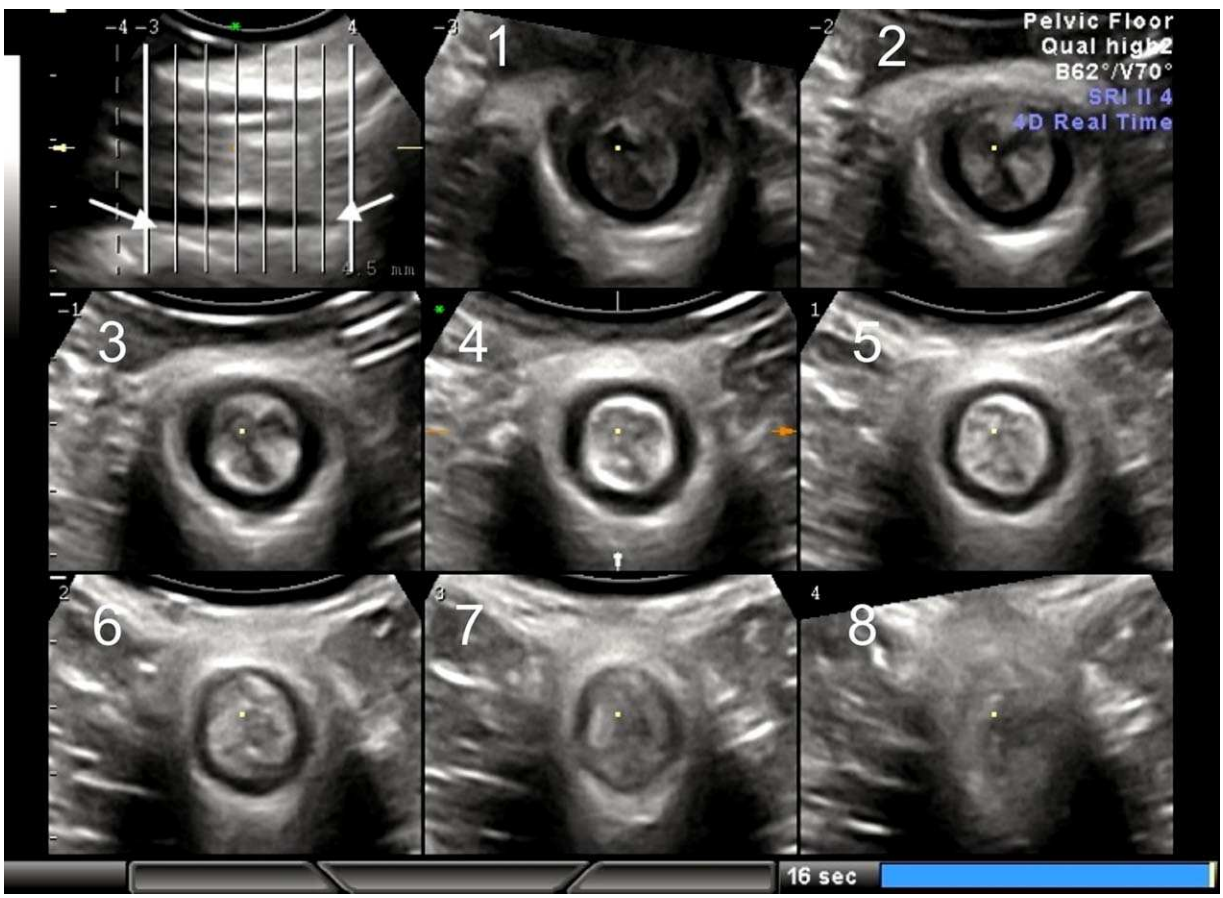

Figure 5. Identification of the cranial extent of the dorsal external sphincter (EAS) with the help of the fascial plane between the levator ani muscle and the external anal sphincter (dotted outlines in **B**). The left white arrows indicate the cranial termination of the external anal sphincter, above which the most cranial slice is placed. The right white arrows mark the caudad termination of the internal sphincter (IAS), below which the most caudad slice is placed.

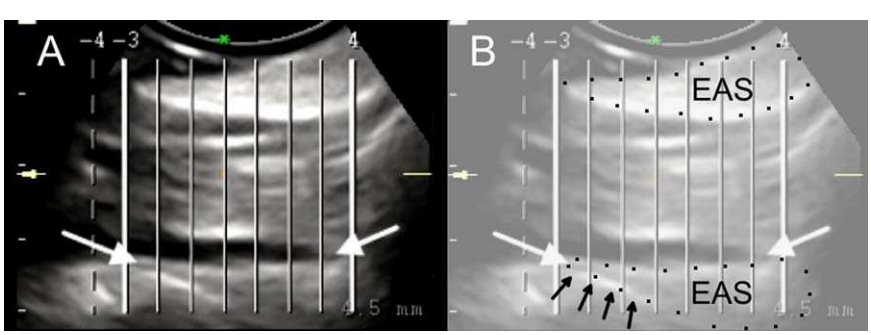

(Figure 6), as it is of similar echogenicity as the external anal sphincter and may seem to be in contiguity with this muscle. In such cases, it may be necessary to extrapolate the "drop shape" of the external anal sphincter. On contraction, the anal canal narrows slightly; the mucosal star may be less pronounced; and defects of the sphincter may become more obvious. On sonography, sphincter defects appear as a discontinuity of the ring shape of the external and internal anal sphincters, with a scar appearing hypoechoic relative to the external anal sphincter and hyperechoic relative to the internal anal sphincter (Figure 7). Most defects are secondary to vaginal childbirth and arise in the ventral aspect of the external and internal anal sphincters. Occasionally, one will observe defects in other locations, and the most common of those seem to be internal anal sphincter defects after hemorrhoidectomy (see below).

On volume acquisition, one needs to take care to retain the entire external anal sphincter within the field of vision toward the end of a pelvic floor muscle contraction maneuver. With acquisition in the transverse plane, as illustrated in Figures 1 and 2, this procedure requires observation of the external anal sphincter location in the B (midsagittal) plane to avoid displacement of the external anal sphincter beyond the acquisition volume. Transverse transducer placement is preferred, as it improves tissue discrimination compared with acquisition in the midsagittal plane. In most women (except for the very obese or elderly), the operator needs to minimize pressure on the perineum, especially if it is deficient, to

Figure 6. Determining the cranial margin of the external sphincter in women with a prominent longitudinal muscle of the anus can be more difficult. The arrows in the reference slice (slice 0) indicate the longitudinal muscle, which appears as an isoechoic continuation of the external anal sphincter. There is no clear demarcation between the longitudinal muscle and the external anal sphincter. A hemorrhoid in slices 6–8 is indicated by asterisks.

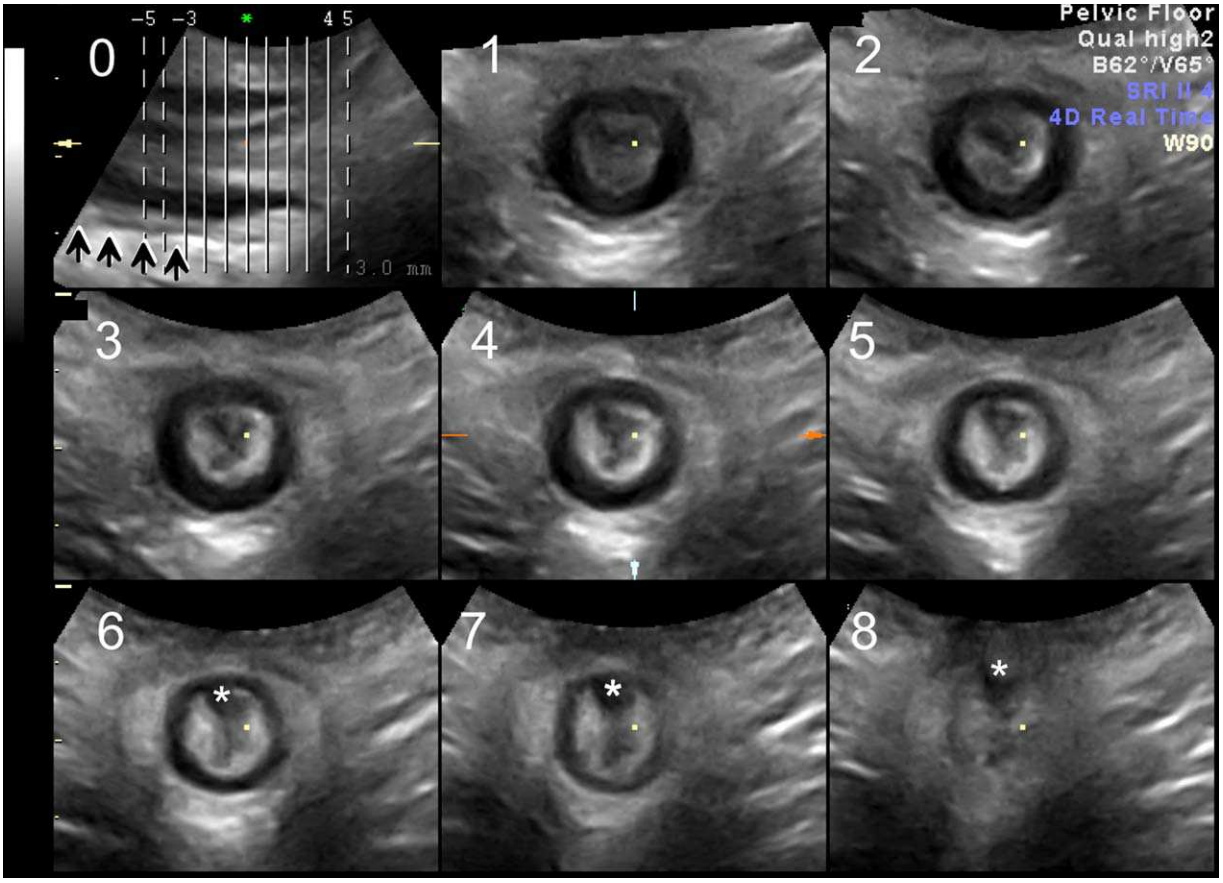

distance the external anal sphincter as much as possible from the transducer surface to avoid compression and deformation of the sphincter (Figure 8).

The transversus perinei muscle can sometimes be quite prominent, as in Figure 7, appearing as a rooflike structure overlying the proximal external anal sphincter; it does, however, vary enormously between individuals. In some women, it seems to clearly decussate into the external anal sphincter (Figure 9), creating a "hose clamp" appearance, but such distinct appearances are not common.

Identification of Sphincter Defects

Tomographic imaging allows for documentation of the entire external anal sphincter from the subcutaneous aspect of the external anal sphincter to its cranial termination, which is identified dorsally to avoid any confounding effect of obstetric anal sphincter trauma (Figures 3–5). Both the caudal termination of the internal anal sphincter and the cranial termination of the external anal sphincter can be determined with good repeatability, which enables the operator to adjust the interstice interval individually, something that is not possible for tomographic imaging of the levator ani muscle.[26] Most commonly, the interslice interval will be set to between 2 and 4 mm.

Defects are usually described by a clock face notation (ie, in hours or degrees) in the coronal plane, as shown in Figures 10 and 11. Most conveniently, a 3-point angle measurement is performed, with the vertex of the angle placed in the center of the anal canal. In the midsagittal or longitudinal plane, sphincter defects can be described by measuring the length of the defect relative to the total sphincter length. The internal anal sphincter seems to commonly show deficiencies

Figure 7. Typical residual external and internal sphincter defect after poor repair of a 3c perineal tear. The transversus perinei seems well repaired, but the external anal sphincter shows a scar that is hypoechoic relative to (darker than) the muscle in slices 2–5. The internal anal sphincter scar is hyperechoic: ie, brighter that the hypoechoic (dark) internal anal sphincter in slices 2–5. Arrows indicate the external anal sphincter defect.

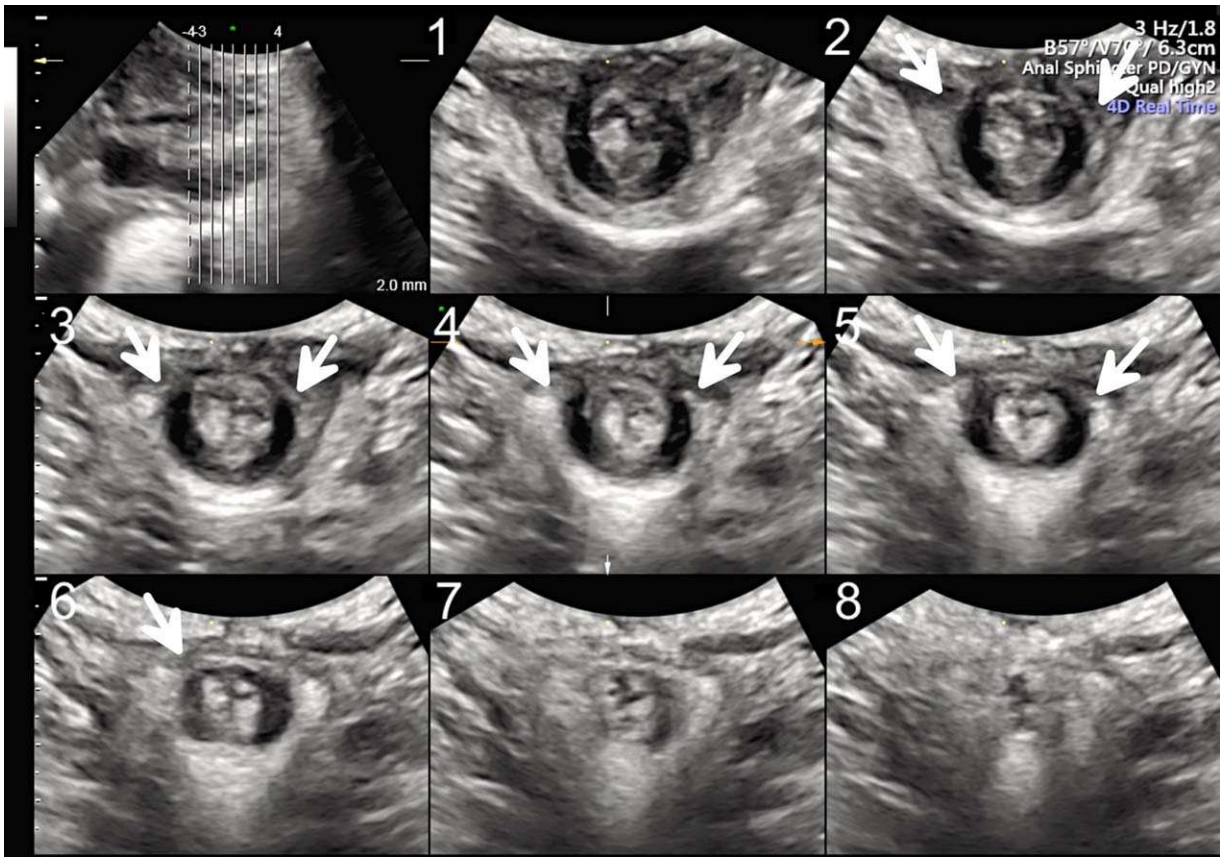

Figure 8. Imaging of the anal sphincters is often improved if one avoids pressure on the perineum, which is facilitated by generous amounts of gel placed centrally and also optimizes imaging of the perineum. The left block of images shows the effect of compression on the perineum, making it harder to assess, and on the anal canal, which appears flattened. The right block of images was obtained without undue pressure, allowing assessment of the perineum and letting the anal canal appear circular in cross section.

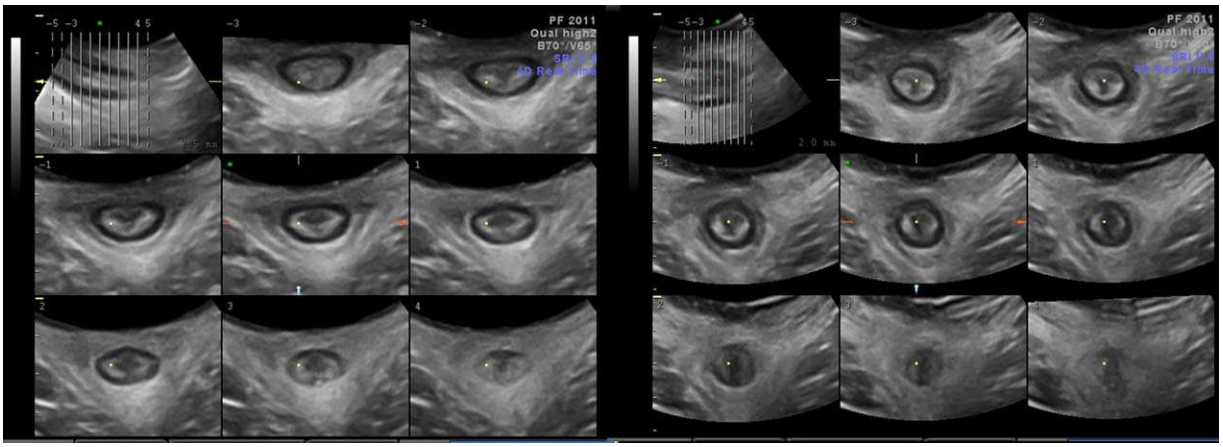

Figure 9. Decussation of transversus perinei fibers into the external sphincter (hose clamp appearance), indicated by arrows. This finding is highly variable.

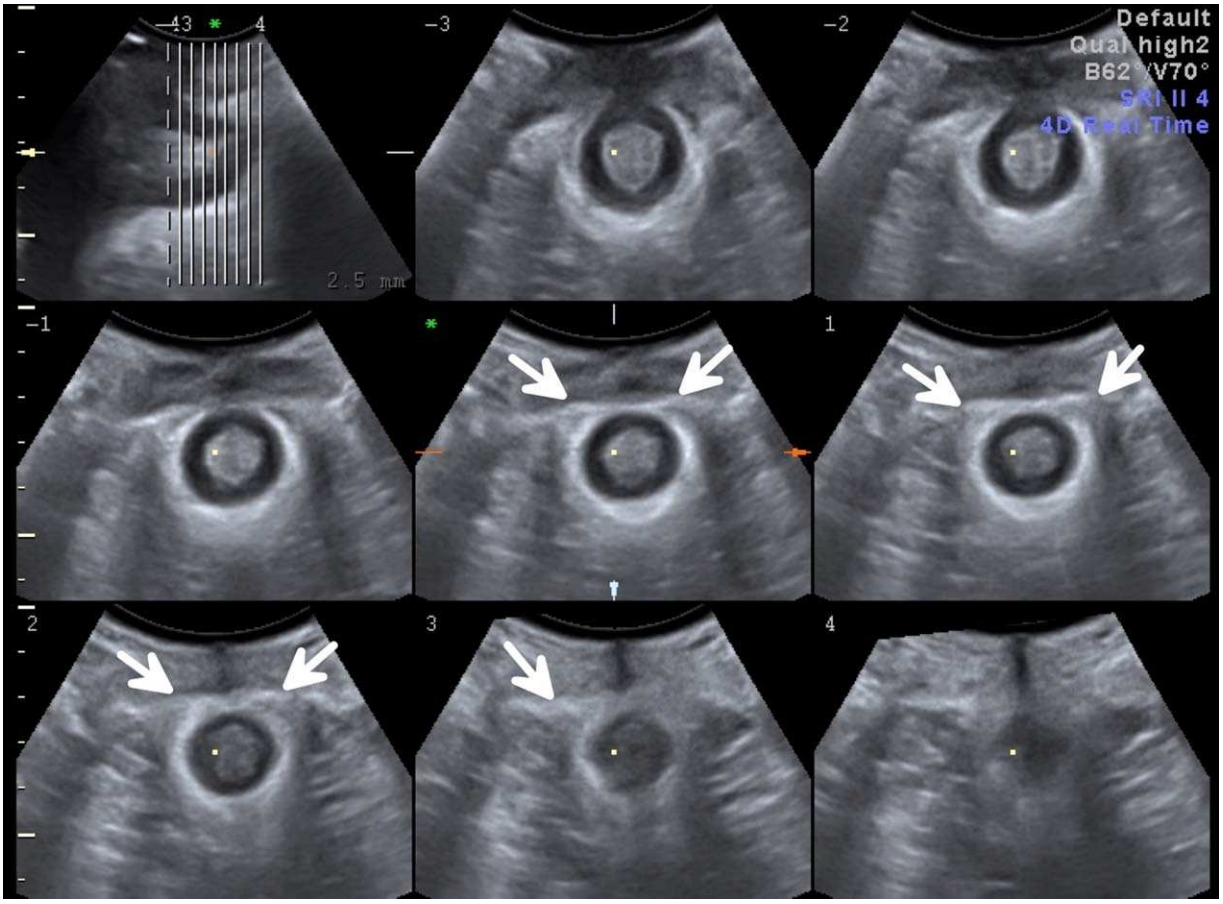

ventrally (between the 10- and 2-o'clock positions) even in nulliparas. It is therefore not surprising that internal anal sphincter defects seem less predictive of anal incontinence than external anal sphincter damage.[20] After sphincter repair, there often is considerable distortion of the anatomy, which is largely absent in women in whom a major perineal tear was overlooked. Figure 11 shows appearances after optimal repair of a mediolateral episiotomy, which resulted in a clean, linear scar. Unfortunately, the operator overlooked a concomitant tear of the external anal sphincter, which remained unrepaired. Figure 12 is a comparison of antenatal and postnatal findings in a patient with an unrecognized 3b (>50% of the external anal sphincter) or possibly 3c tear.

Immediately after childbirth and in the early puerperium, appearances can be confusing. For the first few weeks, suture material, edema, and hematoma may impair appearances to such a degree that external anal sphincter imaging is inconclusive. The internal sphincter seems to be easier to image shortly after childbirth, likely because of its hypoechoic nature,[12] with a defect in the internal anal sphincter causing retraction of the intact muscle and hence a half-moon–like appearance. Often, suture material is evident as hyperechoic spotlike echoes (Figure 13). A steady state seems to be reached after 10 to 12 weeks, which may be the optimal timing for postnatal imaging. Further improvements in appearances after this time seem unlikely,[18] and external anal sphincter defects in elderly women show appearances similar to those detected a few months after childbirth.

A "residual anal sphincter defect" has been defined as a defect of 30° or greater in the circumference of the external anal sphincter in at least 2 of 3 slices on endoanal sonography.[27] As we use 8 tomographic slices, of which 6 are routinely assessed (Figures 10 and 11), it seems reasonable to translate the 2/3 rule of endoanal sonography to a 4/6 rule for translabial or exoanal scanning. The addition of a seventh slice, that is, inclusion of

Figure 10. Old external sphincter defect shown in slices 2–6, with angle measurements between 52° and 71°. The patient was asymptomatic.

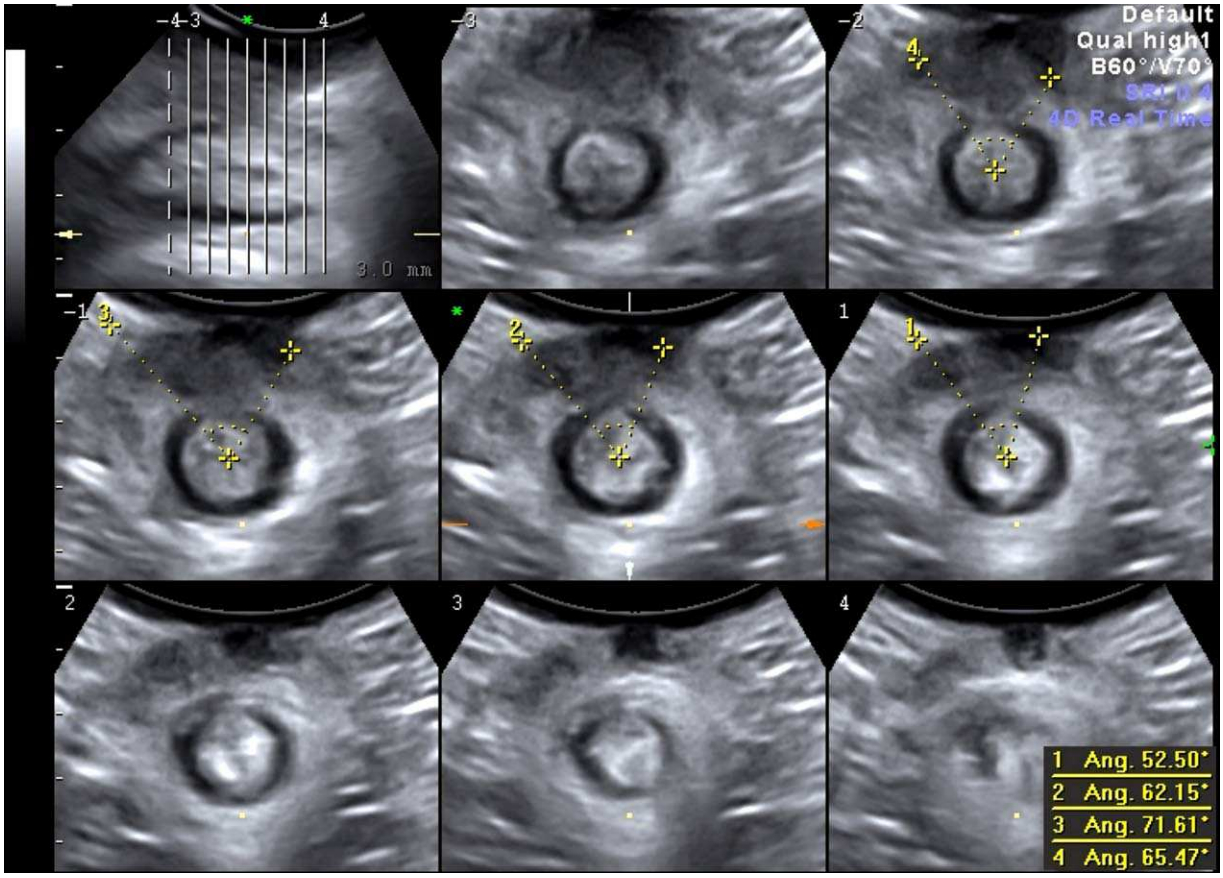

Figure 11. Imaging appearances after episiotomy (hypoechoic scar indicated by arrows). Underneath this well-repaired episiotomy, however, is an unrepaired large 3b tear of the external sphincter.

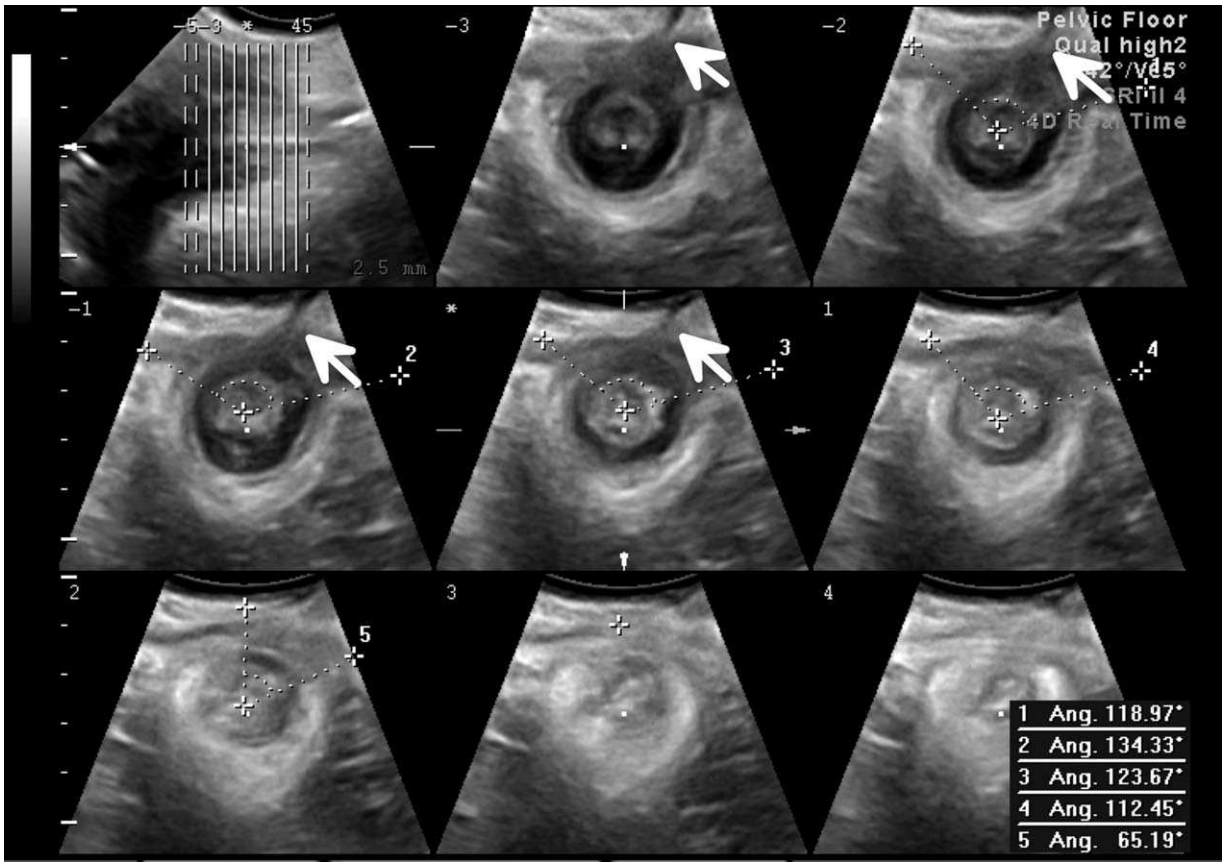

Figure 12. Comparison of images obtained before (**A**) and after (**B**) a delivery resulting in a third-degree tear. In the delivery suite, attending staff documented a second-degree perineal tear. The defect is indicated by asterisks. Reproduced with permission from Guzman Rojas R, Shek K, Langer S, Dietz H. Prevalence of anal sphincter injury in primiparous women. *Ultrasound Obstet Gynecol* 2013; 42:461–466. © 2013 ISUOG.

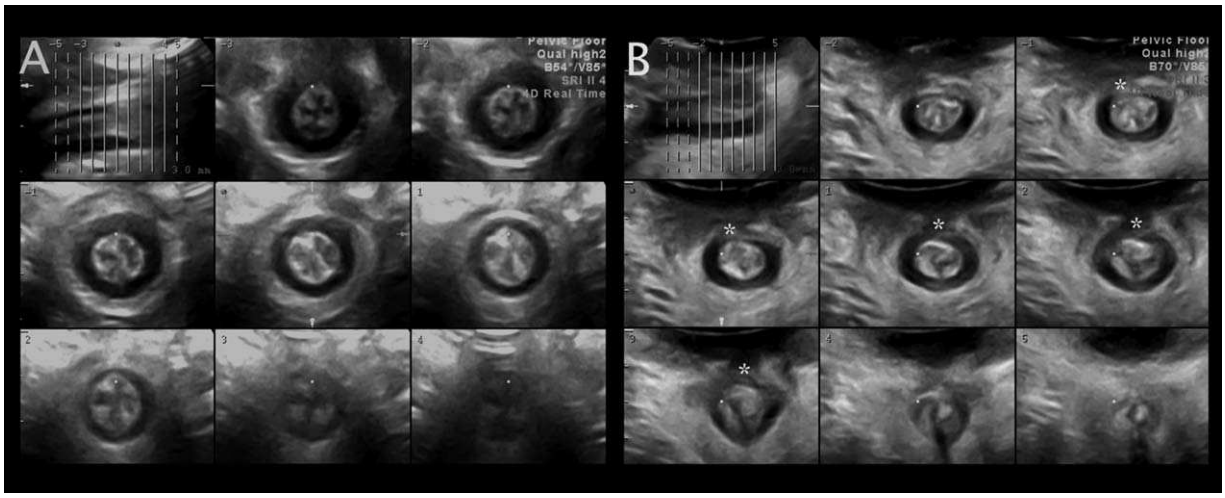

the subcutaneous part of the external anal sphincter in the algorithm for defining a "major defect," does not seem to improve the diagnostic performance of the method.[28] This 4/6 rule seems to distinguish well between symptomatic and asymptomatic women,[29] is highly repeatable,[21] and is very unlikely to yield false-positive results.[30]

As mentioned, a residual defect of the external anal sphincter has been defined as a 30 degree (1-hour) gap in the external anal sphincter circumference (Figure 7). However, a 30° gap in the presence of an endoanal transducer may not equate to a similar- sized defect on exoanal imaging, which is why we have attempted to validate defect angle measurements against symptoms. This attempt has largely been unsuccessful, as defect size seems to matter rather little.[31] The relevance of partial-thickness defects such as the one shown in Figure 14 has yet to be investigated.

Substantial congenital asymmetry of the external anal sphincter could theoretically result in a false-positive diagnosis of sphincter defects in women in whom the dorsal external anal sphincter extends more cranially than its ventral aspect. However, such asymmetry is minor in most women. Hence, the likelihood of a false-positive diagnosis of major defect of the external anal sphincter using the published tomographic method seems low.[29]

A recent comparative study[32] claimed that translabial 4D imaging underestimated external anal sphincter defects, but of course, the truth is likely to be the obverse: endoanal imaging distends defects, overestimating their size. Another comparative study

Figure 13. Appearance of a 3c tear after end-to-end repair. It is evident that a defect remains, which affects part of the external and most of the internal sphincter. Suture material is visible as hyperechoic spots (arrows).

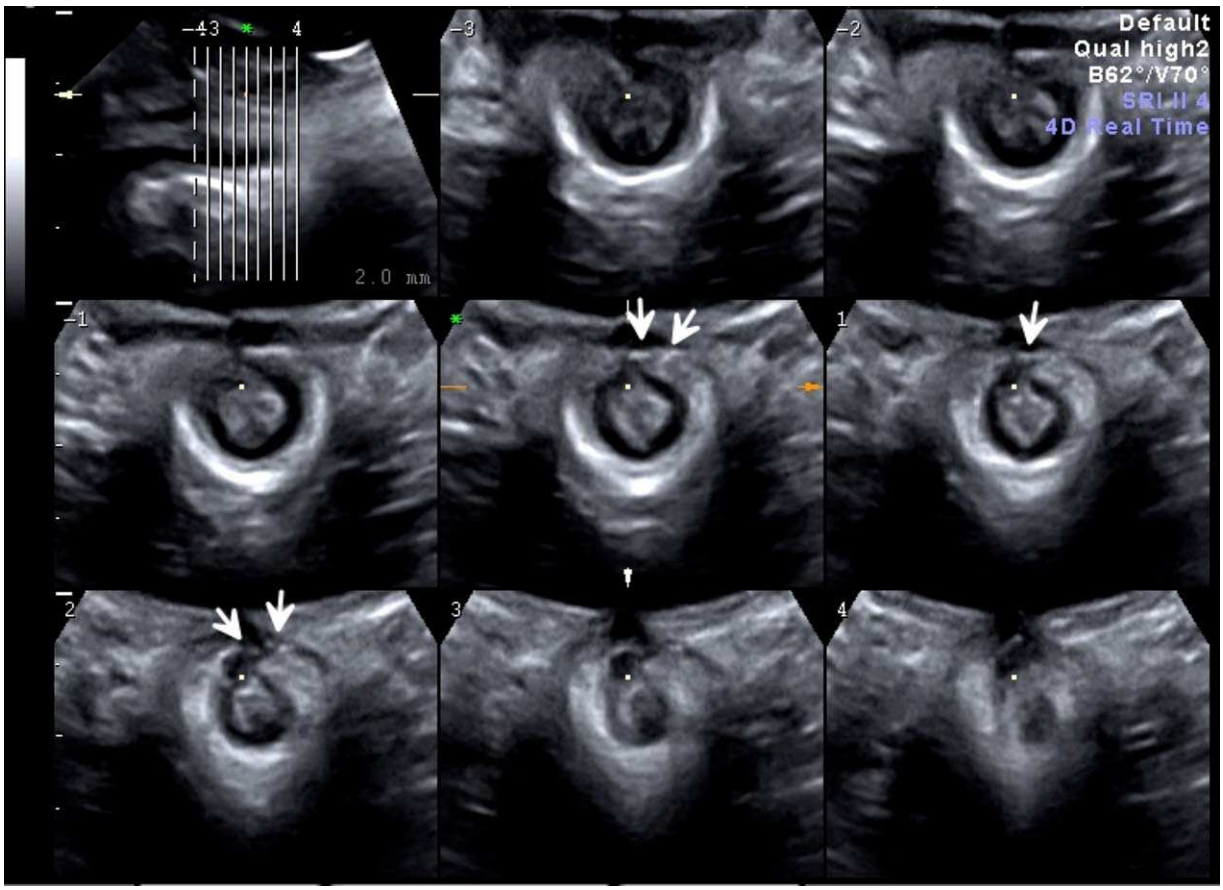

showed a κ value of 0.76 for a comparison of endoanal and translabial sonography, suggesting good agreement.[33]

Prevalence and Risk Factors for Residual External Anal Sphincter Defects

Childbirth and obstetric trauma is by far the dominant cause of anal sphincter defects. It is recognized as the main etiological factor for anal incontinence in women and has become a growing source of obstetric litigation. The main risk factor is considered to be instrumental vaginal delivery,[34] with forceps clearly more dangerous than a vacuum-assisted delivery.[17,35] Anal incontinence is common after third- and fourth-degree tears, even if recognized and repaired at the time of injury, and can have a major deleterious effect on a woman's quality of life.[36] The condition may be underreported in the literature because of the social stigma involved. Early recognition and repair of sphincter injuries are likely to be beneficial.[37]

Residual anal sphincter defects are commonly observed on imaging in women after a first vaginal delivery, at a prevalence rate of between 10% and 25%.[17,38,39] In general, anal sphincter injuries seem to occur much more frequently than previously reported, although this situation may well be due to ineffective intrapartum detection rather than covered, truly "occult" defects.[38] Either way, prevalence figures given in the literature are very likely to be substantial underestimates, and comparisons between studies, institutions, or individuals are of very limited use until such time as standardized imaging information is available. Interestingly, parity does not seem to be positively associated with prevalence,

Figure 14. Partial-thickness external anal sphincter tear (arrows) in a patient without a history of an anal sphincter tear. The clinical relevance of such findings is uncertain.

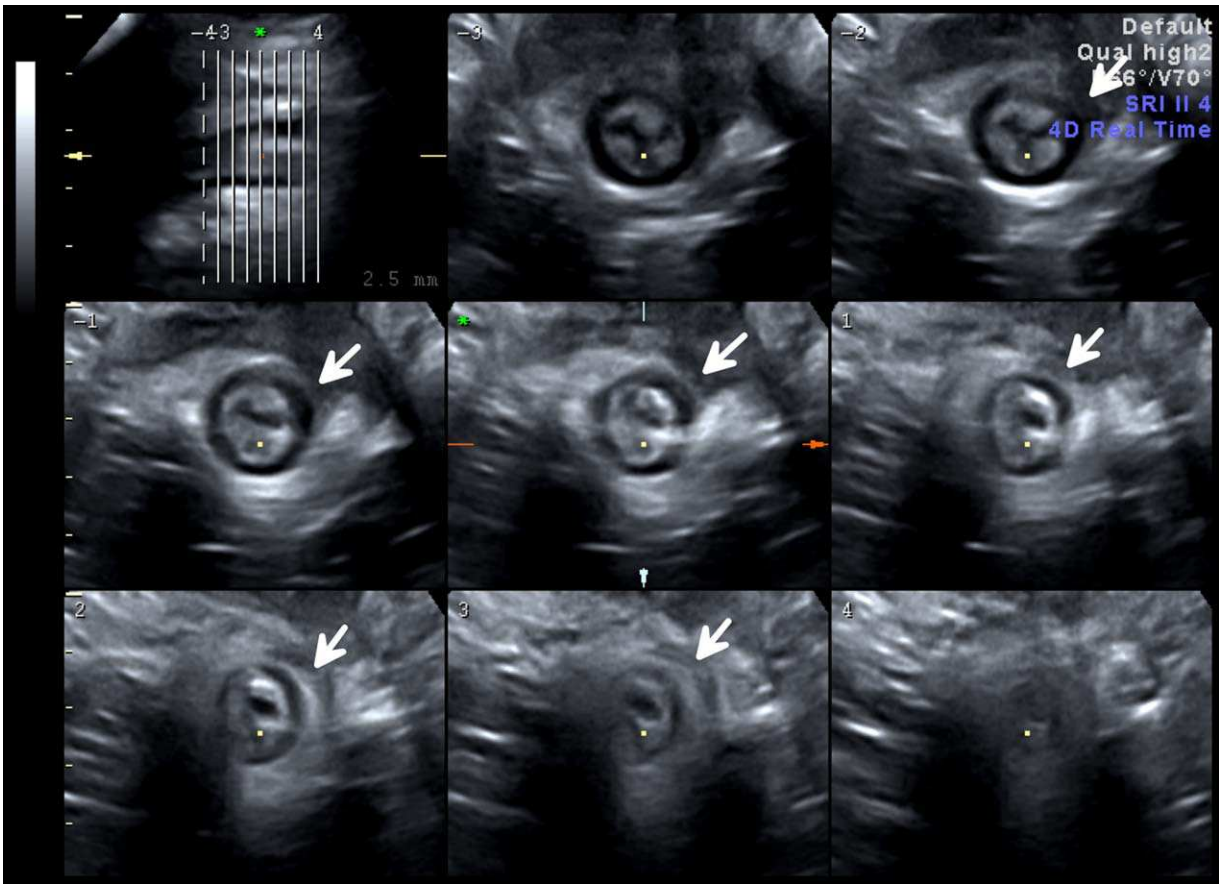

suggesting that most external anal sphincter trauma occurs at the time of a first vaginal delivery, as is true for levator injury.[19,40]

Unfortunately, sphincter imaging in women after a first vaginal birth is likely to uncover a large proportion of undiagnosed tears, which explains why the prevalence of sonographic defects in cohort studies[40,41] and in urogynecologic populations[17] is so much higher than obstetric anal sphincter trauma rates reported in the literature.[42] Clearly, there is much scope for improved clinical diagnosis immediately after childbirth.[38]

However, even if a major perineal tear is accurately diagnosed in the delivery suite, it is often not well repaired.[16] Sonography frequently shows residual defects (Figures 7, 13, and 15). The extent of such defects seems associated with decreased sphincter pressures and an increased risk of anal incontinence,[16,43–46] even if symptoms may only develop many years later.[36] Figure 13 shows a fair end-to-end repair with a residual defect, Figure 15 is a mediocre result after an overlap repair of a 3c tear, and Figure 16 shows a small rectovaginal fistula after poor repair of a 3c tear.

The greatest utility of exoanal sphincter imaging will likely be in postnatal follow-up, especially after a first vaginal delivery. To date, endoanal sonography has not made a major contribution to postnatal care, largely because of the invasiveness of the procedure and the need for additional specialized and expensive equipment. This situation has prompted a search for other imaging modalities.[42] The noninvasive nature of exoanal imaging and the ease with which it can be combined with assessment of the levator ani opens up the possibility of

Figure 15. Status after a fair overlap repair of a 3C tear, showing only minor distortion (arrows) and a well-approximated perineal scar. Reconstruction of the internal sphincter is poor, leaving a large residual defect.

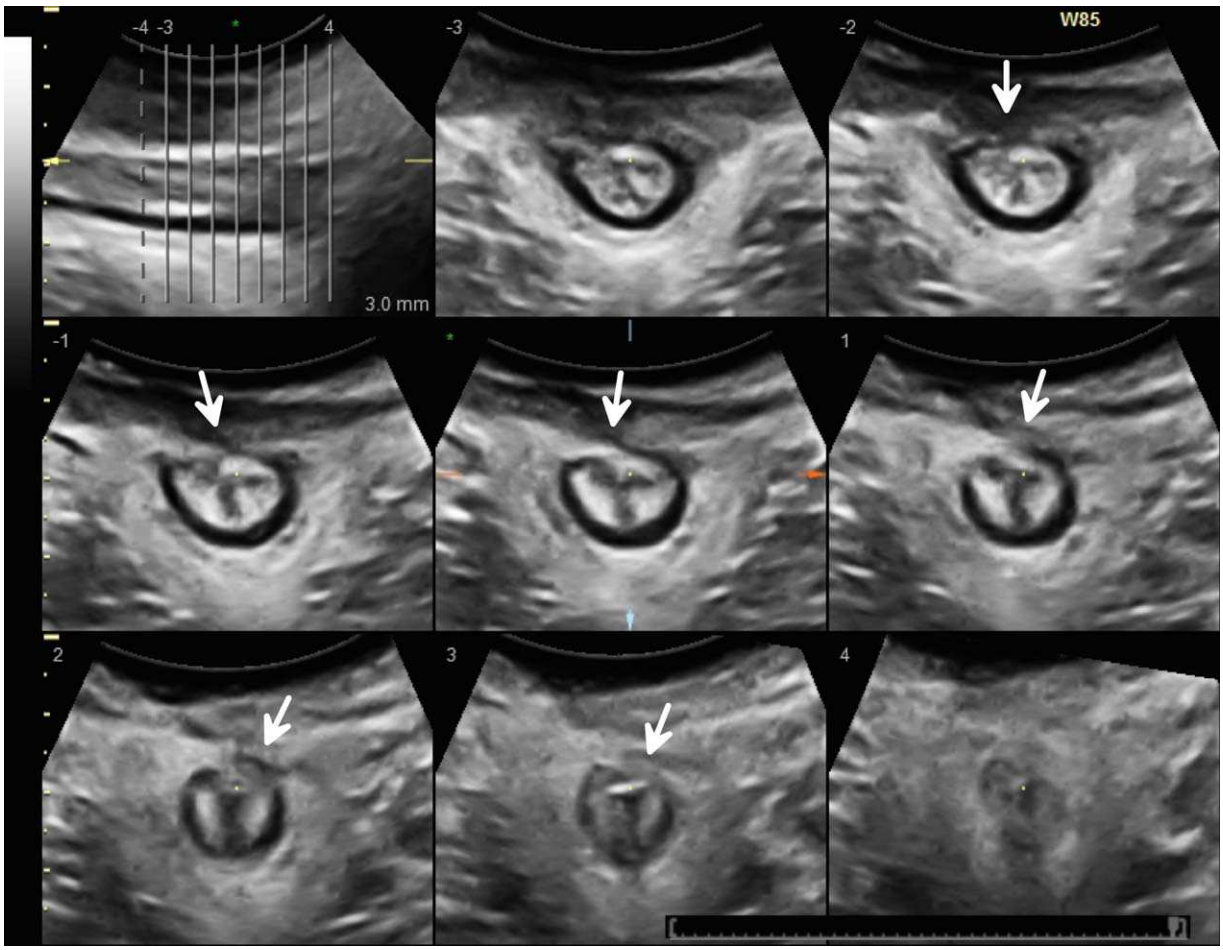

performing a comprehensive pelvic floor assessment after a first vaginal birth, allowing obstetric quality control and early intervention in women with substantial trauma. Hence, the method would allow services to make maternal birth trauma a key performance indicator of obstetric services.[22] If individuals and institutions were interested in better detection and management of maternal birth trauma, routine postnatal imaging could be offered to women after a first vaginal birth.[22] Another benefit of postnatal imaging would be the opportunity to audit results after obstetric anal sphincter trauma repair, which is not commonly undertaken at present. However, any attempt at improving outcomes, whether by a clinical audit or in the context of randomized controlled trials, may have to use sphincter imaging rather than anal incontinence as an outcome measure, as the latter may only become manifest many years after a sphincter tear.[36]

Incidental Findings

Not infrequently, exoanal imaging of the anal canal will uncover abnormalities that clearly are not the result of obstetric trauma. Hemorrhoids are common and may cause difficulties in the identification of the caudal margin of the internal anal sphincter, as shown in Figure 17. The more distortion and acoustic artifacts, the greater these difficulties, especially in acutely inflamed, thrombosed hemorrhoids, as in this patient. At times, a ventral hemorrhoid may cause appearances vaguely similar to an external anal sphincter tear, as evident in slices 6–8 of Figure 17. However, hemorrhoids more commonly

Figure 16. Small rectovaginal fistula 3 months after an insufficiently repaired 3c tear. The fistula is a small filiform echogenic line, indicated by arrows in 2 central slices. The arrows in the top left image indicate the longitudinal extent of the internal anal sphincter defect.

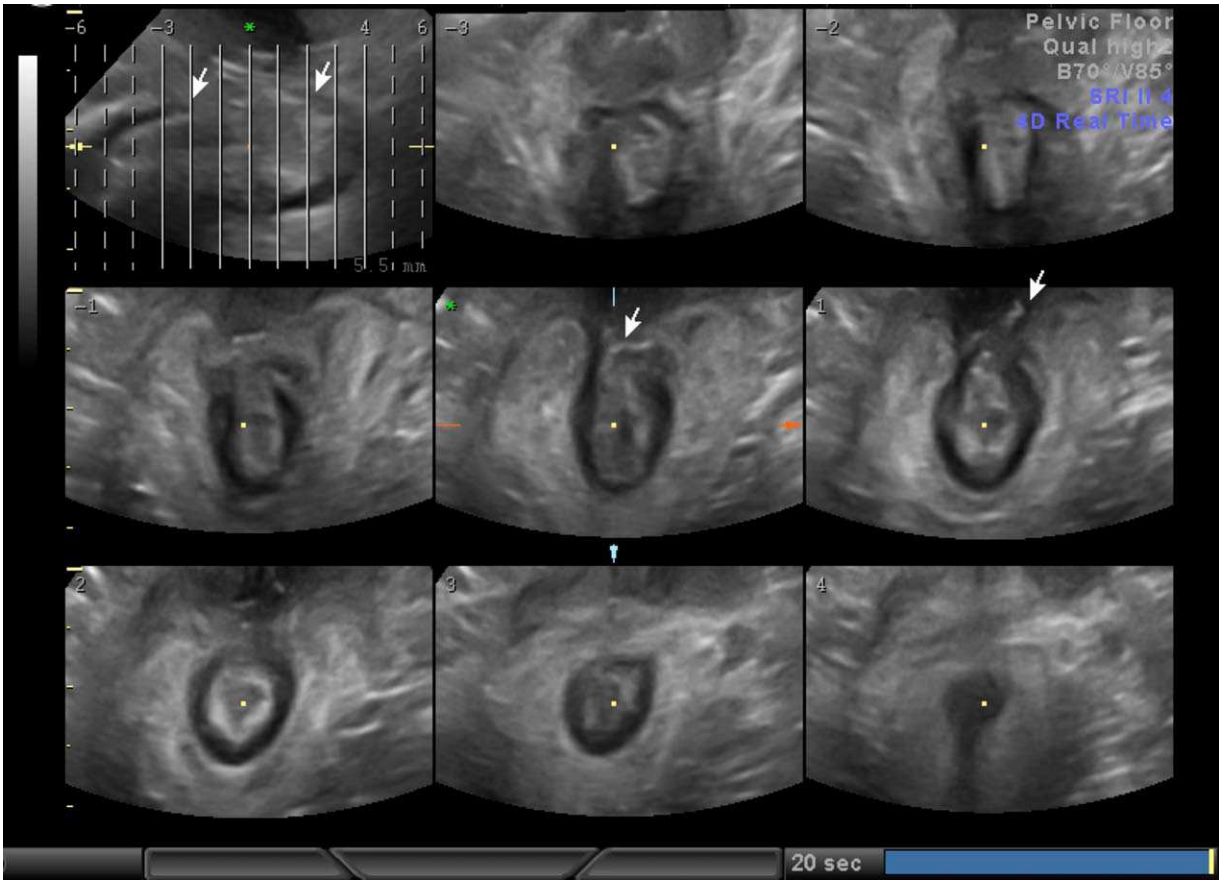

affect the most caudad part of the sphincter apparatus and arise from the mucosal star so that the distinction is not that difficult.

Hemorrhoidectomy, on the other hand, can cause highly specific appearances, as shown in Figure 18. Apparently, the internal anal sphincter in this patient was inadvertently split in the 5-o'clock position: ie, she had an inadvertent internal sphincterotomy. Such appearances explain why hemorrhoidectomy is commonly recognized as a risk factor for anal incontinence.[47,48]

Translabial sphincter imaging yet has to be used for purely colorectal indications, but this method may have substantial utility in such patients. Figure 19 shows its potential in a patient with a perineal abscess, and Figure 20 shows appearances after surgical treatment of a perianal fistula.

What About Endoanal Imaging?

Several studies have been undertaken to compare exoanal with endoanal sphincter imaging,[15,32,33] all showing moderate to good agreement between the methods. However, to date, none have validated the different methods against symptoms. Several such studies are currently in progress. Validation of competing methods can be undertaken by testing the sensitivity and specificity of those methods for the prediction of symptoms of anal incontinence. To show superior performance of one method over another (ie, statistically significantly different areas under the curve on receiver operator characteristic statistics) may be difficult without the acquisition of large data sets.

However, relative diagnostic performance is only one aspect of any comparison, which would also require

Figure 17. Inflamed hemorrhoid on tomographic imaging, indicated by arrows. Hemorrhoids can obscure the distal aspect of the internal anal sphincter and sometimes even the external sphincter, interfering with the assessment.

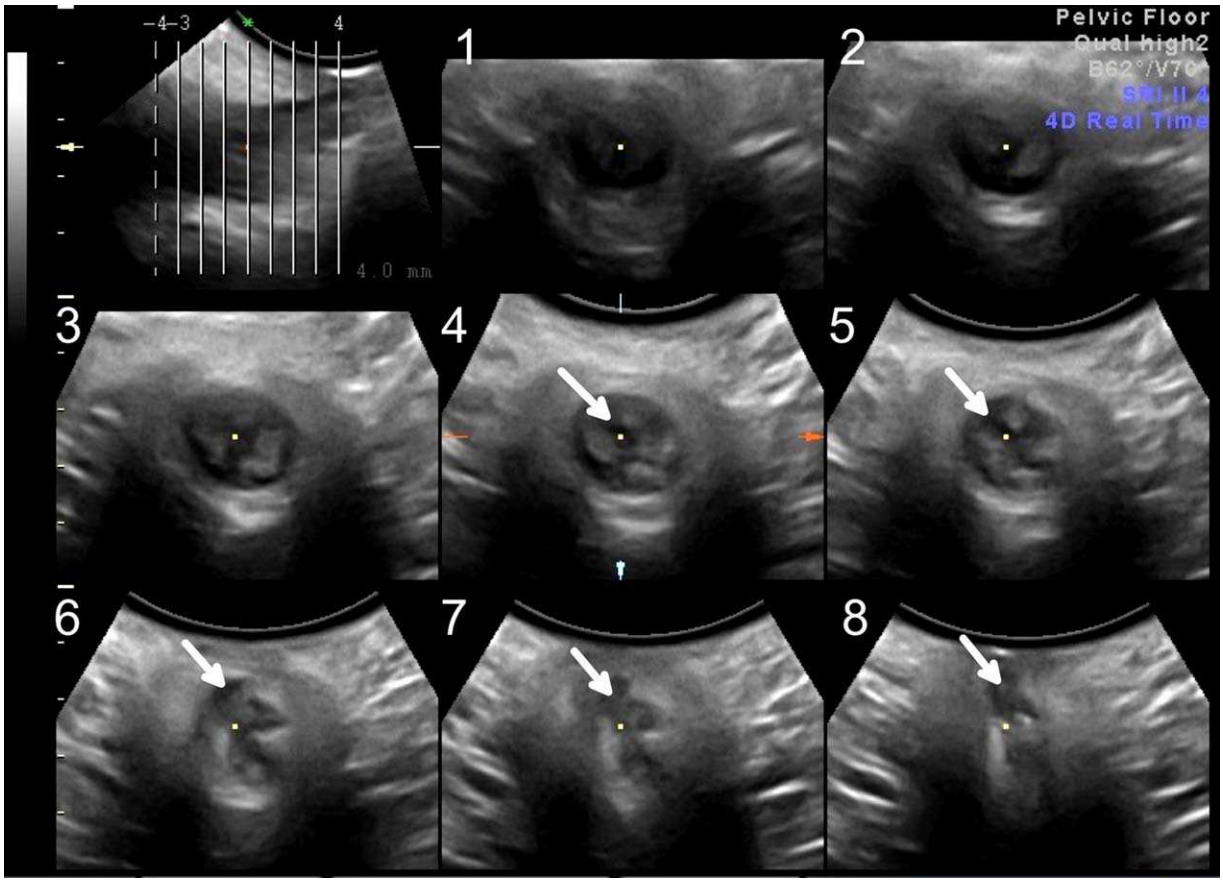

consideration of patient bother, cost, and system availability. Exoanal imaging is, at least potentially, much more widely available and very likely to be less expensive and obviously less bothersome to the patient.[32] These factors imply that the method is much more likely to have a positive impact on both clinical practice and research, which is of crucial importance, especially given the recent rise of forceps delivery in some jurisdictions.[49] In addition, exoanal 3D/4D imaging has the advantage that it can very easily be combined with an assessment of levator integrity and pelvic organ descent. It appears likely that all 3 tasks will be accomplished as part of what we term "pelvic floor sonography": a 10-to 15-minute examination that provides a wealth of information, which would otherwise require magnetic resonance imaging for levator ani integrity, dynamic magnetic resonance imaging for organ descent, defecation proctography for the assessment of posterior compartment anatomy, and endoanal sonography for sphincter imaging.

Outlook

Pelvic floor sonography is likely to play a major role in the evaluation of patients after traumatic delivery, as it is almost universally available because of the widespread uptake of 3D/ 4D imaging by perinatal ultrasound departments. There are substantial opportunities not just for clinical research but also for practice improvement and clinical audit. The high prevalence of residual external anal sphincter residual defects after sphincter repair and, even more so, the fact that most external anal sphincter tears seem to be missed immediately after childbirth, show clearly that we should be able to do much better in diagnosing and repairing those tears. In terms of prevention, the most urgent task seems to be to

Figure 18. Status after hemorrhoidectomy in 60-year-old patient with mild anal incontinence. The internal anal sphincter is invisible between the 4- and 7-o'clock positions in most slices and thickened over the remaining circumference, indicating iatrogenic trauma.

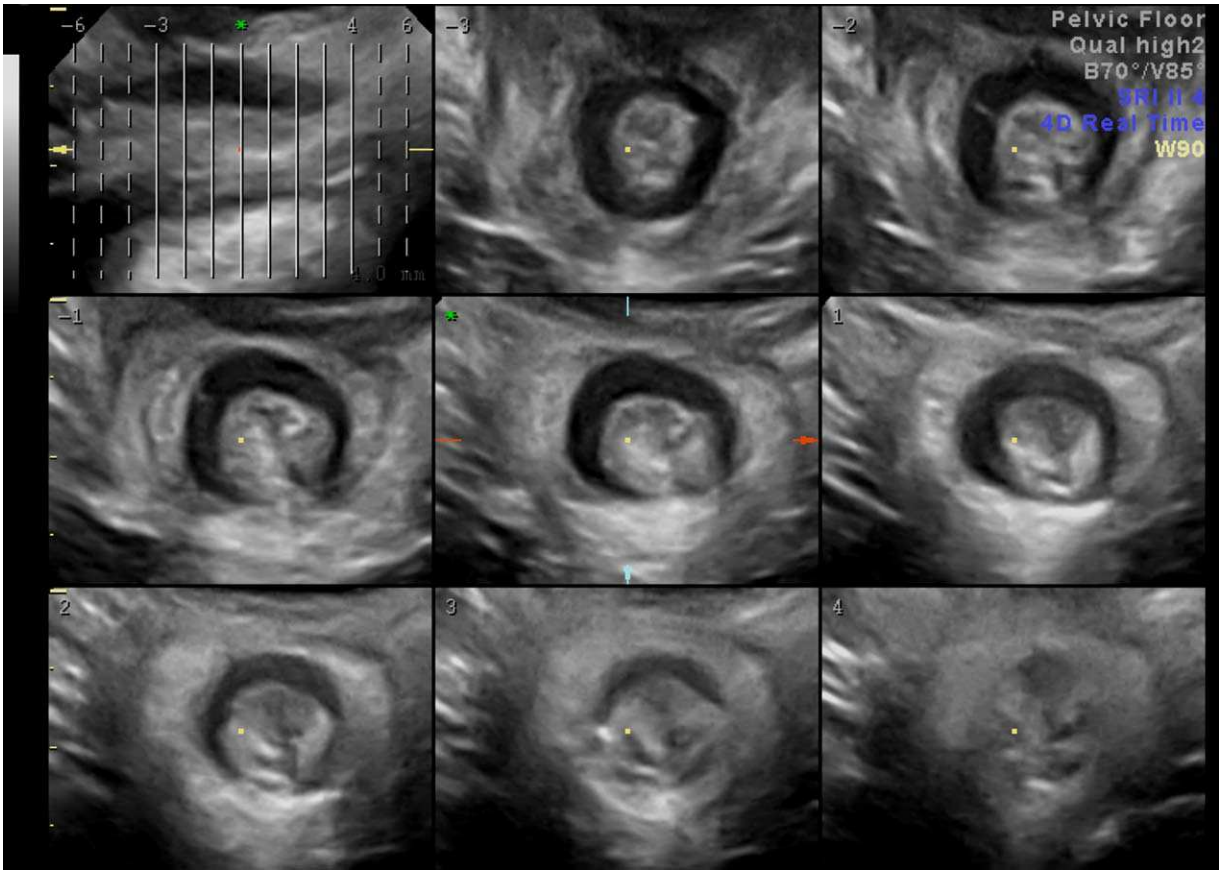

Figure 19. Perianal abscess (arrows).

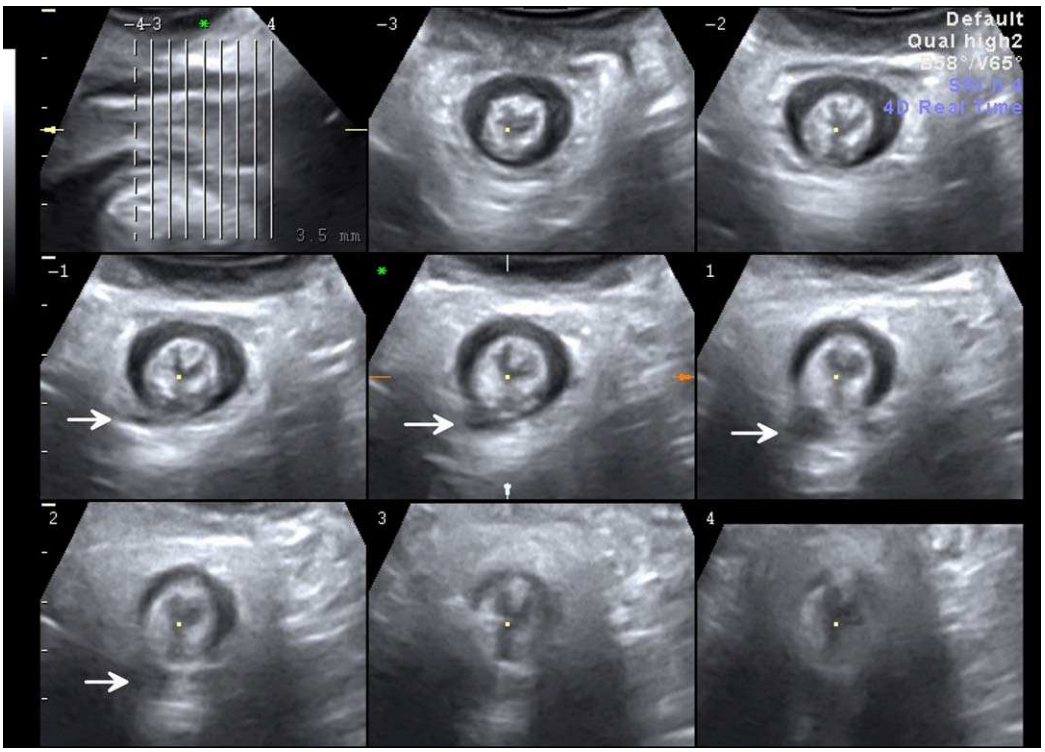

Figure 20. Scarring and external/internal sphincter defects in a typical location after surgical treatment of a perianal fistula (arrows).

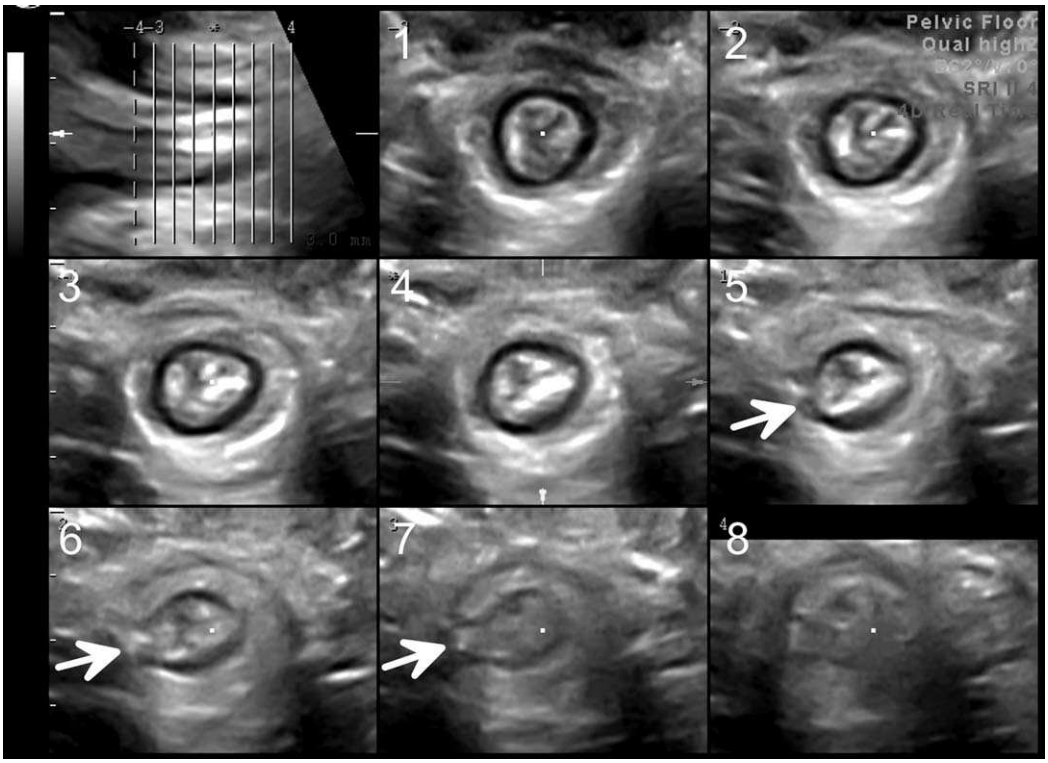

reduce forceps deliveries,[35,36,49] which is much more likely to occur if the resulting damage is properly diagnosed rather than ignored. The widespread availability of sphincter imaging will be crucial for this task.

At this point in time, the main obstacle is not cost (which would be minimal) but, rather, the limited availability of teaching. In some jurisdictions, such as in the United Kingdom, Australia, and New Zealand, there may also be substantial resistance to any diagnostic intervention that draws attention to negative consequences of vaginal childbirth.[22,50] Unfortunately, in some jurisdictions, change may only occur as a result of public and medicolegal pressure.

References

1. Starck M, Bohe M, Valentin L. Results of endosonographic imaging of the anal sphincter 2–7 days after primary repair of third- or fourth-degree obstetric sphincter tears. *Ultrasound Obstet Gynecol* 2003; 22: 609–615.
2. Damon H, Henry L, Bretones S, Mellier G, Minaire Y, Mion F. Post-delivery anal function in primiparous females: ultrasound and manometric study. *Dis Colon Rectum* 2000; 43:472–477.
3. Williams AB, Bartram CI, Halligan S, et al. Alteration of anal sphincter morphology following vaginal delivery revealed by multiplanar anal endosonography. *BJOG* 2002; 109:942–946.
4. Gold DM, Bartram CI, Halligan S, Humphries KN, Kamm MA, Kmiot WA. Three-dimensional endoanal sonography in assessing anal canal injury. *Br J Surg* 1999; 86:365–370.
5. Sultan AH. The role of anal endosonography in obstetrics [comment]. *Ultrasound Obstet Gynecol* 2003; 22:559–560.
6. Peschers UM, DeLancey JO, Schaer GN, Schuessler B. Exoanal ultrasound of the anal sphincter: normal anatomy and sphincter defects. *Br J Obstet Gynaecol* 1997; 104:999–1003.
7. Roche B, Deleaval J, Fransioli A, Marti M. Comparison of transanal and external perineal ultrasound. *Eur Radiol* 2002; 11:1165–1170.
8. Lohse C, Bretones S, Boulvain M, Weil A, Krauer F. Trans-perineal versus endo-anal ultrasound in the detection of anal sphincter defects. *Eur J Obstet Gynaecol* 2002; 103:79–82.
9. Timor-Tritsch IE, Monteagudo A, Porges RF, Santos R. Simple ultrasound evaluation of the anal sphincter in female patients using a transvaginal transducer. *Ultrasound Obstet Gynecol* 2005; 25:177–183.
10. Yagel S, Valsky DV. Three-dimensional transperineal sonography for evaluation of the anal sphincter complex: another dimension in understanding peripartum sphincter trauma. *Ultrasound Obstet Gynecol* 2006; 27:119–123.
11. Lee J, Pretorius D, Weinstein MM, Guaderrama N, Nager CW, Mittal R. Transperineal three-dimensional ultrasound in evaluating anal sphincter muscles. *Ultrasound Obstet Gynecol* 2007; 30:201–209.
12. Valsky DV, Malkiel A, Savchev S, Messing B, Hochner-Celnikier D, Yagel S. 3D transperineal ultrasound follow-up of intrapartum anal sphincter tears and functional correlation with clinical complaints [abstract]. *Ultrasound Obstet Gynecol* 2007; 30(suppl):449.
13. Huang W, Yang S, Yang J. Three-dimensional transperineal sonographic characteristics of the anal sphincter complex in nulliparous women. *Ultrasound Obstet Gynecol* 2007; 30:210–220.
14. van de Geest L, Steensma AB. Three-dimensional transperineal ultrasound imaging of anal sphincter injuries after surgical primary repair [abstract]. *Ultrasound Obstet Gynecol* 2010; 36(suppl 1):270.
15. Oom DMJ, West CR, Schouten WR, Steensma AB. Detection of anal sphincter defects in female patients with fecal incontinence: a comparison of 3-dimensional transperineal ultrasound and 2-dimensional endoanal ultrasound. *Dis Colon Rectum* 2012; 55:646–652.
16. Shek K, Guzman Rojas R, Dietz HP. Residual defects of the external anal sphincter following primary repair: an observational study using transperineal ultrasound. *Ultrasound Obstet Gynecol* 2014; 44:704–709.
17. Guzman Rojas R, Shek K, Langer S, Dietz H. Prevalence of anal sphincter injury in primiparous women. *Ultrasound Obstet Gynecol* 2013; 42:461–466.
18. Shek KL, Della Zazzera V, Kamisan Atan I, Guzman Rojas R, Langer S, Dietz HP. The evolution of transperineal ultrasound findings of the external anal sphincter during the first years after childbirth. *Int Urogynecol J* 2016; 27:1899–1903.
19. Kamisan Atan I, Lin S, Herbison P, Dietz H, Wilson P. It's the first vaginal birth that does most of the damage [abstract]. *Int Urogynecol J* 2015; 26(suppl 1):S46–S47.
20. Guzman Rojas R, Shek KL, Kamisan Atan I, Dietz HP. Anal sphincter trauma and anal incontinence in urogynecological patients. *Ultrasound Obstet Gynecol* 2015; 46:363–366.
21. Subramaniam N, Bienkiewicz J, Friedman T, Turel F, Dietz H. How repeatable are measures of anal sphincter trauma by exo-anal 4D ultrasound? *Int Urogynecol J*. In press.
22. Dietz HP, Pardey J, Murray HG. Maternal birth trauma should be a key performance indicator of maternity services. *Int Urogynecol J* 2015; 26:29–32.
23. Subramaniam N, Brown C, Dietz H. Anal sphincter imaging: at rest or on PFMC? *Int Urogynecol J*. In press.
24. Guzman Rojas R, Kamisan Atan I, Caudwell-Hall J, Dietz H. Internal anal sphincter thickness as a predictor of obstructed defaecation [abstract]. *Ultrasound Obstet Gynecol* 2014; 44(suppl 1):95.
25. Dietz H, Bernardo M, Kirby A, Shek K. Minimal criteria for the diagnosis of avulsion of the puborectalis muscle by tomographic ultrasound. *Int Urogynecol J* 2011; 22:699–704.
26. Subramaniam N, Dietz H. What is a "significant defect" of the anal sphincter [abstract]? *Int Urogynecol J* 2016; 27(suppl 1):S55–S56.
27. Roos AM, Thakar R, Sultan AH. Outcome of primary repair of obstetric anal sphincter injuries (OASIS): does the grade of tear matter? *Ultrasound Obstet Gynecol* 2010; 36:368–374.

28. Subramaniam N, Brown C, Dietz H. Does the seventh slice matter? *Int Urogynecol J*. In press.
29. Magpoc J, Kamisan Atan I, Dietz H. Normal values of anal sphincter biometry by 4-dimensional pelvic floor ultrasound [abstract]. *J Ultrasound Med* 2016; 35(suppl):S53.
30. Turel F, Shek K, Dietz H. Tomographic imaging of the anal sphincter: limits of normality. *Int Urogynecol J*. In press.
31. Subramaniam N, Brown C, Dietz H. EAS defect size: does it matter? *Int Urogynecol J*. In press.
32. Van Gruting I, Arendsen L, Naiu M, Thakar R, Sultan A. Can transperineal ultrasound replace endoanal ultrasound for the detection of anal sphincter defects [abstract]? *Int Urogynecol J* 2016; 27(suppl 1):S51–S52.
33. Ros C, Martínez-Franco E, Wozniak M, et al. Postpartum two- and three-dimensional ultrasound evaluation of anal sphincter complex in women with obstetric anal sphincter injury. *Ultrasound Obstet Gynecol* 2017; 49:508–514.
34. Sultan AH, Kamm MA, Hudson CN, Thomas JM, Bartram CI. Anal sphincter disruption during vaginal delivery. *N Engl J Med* 1993; 329: 1905–1911.
35. Friedman T, Eslick G, Dietz H. Instrumental delivery and OASI [abstract]. *Int Urogynecol J* 2016; 27(suppl 1):S30–S31.
36. Thornton M, Lubowski D. Obstetric-induced incontinence: a black hole of preventable morbidity. *Aust NZ J Obstet Gynaecol* 2006; 46:468–473.
37. Faltin DL, Boulvain M, Floris LA, Irion O. Diagnosis of anal sphincter tears to prevent fecal incontinence: a randomized controlled trial. *Obstet Gynecol* 2005; 106:6–13.
38. Andrews A, Sultan A, Thakar R, Jones P. Occult anal sphincter injuries: myth or reality? *BJOG* 2006; 113:195–200.
39. Corton MM, McIntire D, Twickler D, Atnip S, Schaffer J, Leveno K. Endoanal ultrasound for detection of sphincter defects following childbirth. *Int Urogynecol J* 2014; 24:627–635.
40. Li Y, Subramaniam N, Friedman T, Dietz HP. Parity and anal sphincter trauma. *Ultrasound Obstet Gynecol*. In press.
41. Kamisan Atan I, Langer S, Shek K, Caudwell Hall J, Guzman Rojas R, Dietz H. Does the EPI-No prevent pelvic floor trauma? A multicentre randomised controlled trial. *BJOG* 2016; 123:995–1003.
42. Abdool Z, Sultan A, Thakar R. Ultrasound imaging of the anal sphincter complex: a review. *Br J Radiol* 2012; 85:865–875.
43. Starck M, Bohe M, Valentin L. The extent of endosonographic anal sphincter defects after primary repair of obstetric sphincter tears increases over time and is related to anal incontinence. *Ultrasound Obstet Gynecol* 2006; 27:188–197.
44. Norderval S, Markskog A, Rossaak K, Vonen B. Correlation between anal sphincter defects and anal incontinence following obstetric sphincter tears: assessment using scoring systems for sonographic classification of defects. *Ultrasound Obstet Gynecol* 2008; 31:78–84.
45. Faltin D, Sangalli M, Roache B, Floris L, Boulvain M, Weil A. Does a second delivery increase the risk of anal incontinence? *BJOG* 2001; 108:684–688.
46. Oude Lohuis E, Everhardt E. Outcome of obstetric anal sphincter injuries in terms of persisting endoanal ultrasonographic defects and defecatory symptoms. *Int J Gynaecol Obstet* 2014; 126:70–73.
47. Holzheimer R. Hemorrhoidectomy: indications and risks. *Eur J Med Res* 2004; 26:18–36.
48. Zbar A, Beer-Gabel M, Chiappa A, Aslam M. Fecal incontinence after minor anorectal surgery. *Dis Colon Rectum* 2001; 44:1610–1619.
49. Dietz H. Forceps: towards obsolescence or revival? *Acta Obstet Gynecol Scand* 2015; 94:347–351.
50. Dietz HP, Campbell S. Towards normal birth: but at what cost? *Am J Obstet Gynecol* 2016; 215:439–444.